

Carrion's disease after blood transfusion

Maria J. Pons¹, Pedro Lovato², Jaquelyne Silva², Numan Urteaga², Juana del Valle Mendoza¹, Joaquim Ruiz³

¹Research Centre of the Faculty of Health Sciences, Peruvian University of Applied Sciences - UPC, Lima, Peru;

²Hematology Service, Regional Hospital of Cajamarca, Cajamarca, Peru; ³ISGlobal, Barcelona Centre for International Health Research (CRESIB), Hospital Clínic - University of Barcelona, Barcelona, Spain

Introduction

Bartonella bacilliformis is a pathogen that is endemic in some areas of the Andean region of Peru, southern Ecuador and southern Colombia. This pathogen causes so-called Carrion's disease, a biphasic disease with acute and chronic phases (called Oroya fever and "Peruvian wart" respectively¹⁻³). In the absence or delay of antibiotic treatment, the mortality rate in the acute phase is up to 88%¹. The acute phase is characterised by fever and severe anaemia and may be followed, several weeks or months later, by the chronic eruptive phase due to endothelial cell proliferation². No animal reservoir has been identified to date and it is considered that healthy carriers act as a pathogen reservoir in endemic areas⁴.

B. bacilliformis is transmitted by sand-fly bites by members of the *Lutzomyia* genus³, although other mechanisms have been proposed such as mother-to-child vertical transmission⁵, or transfer through contaminated blood during transfusions or accidental contact². Several *Bartonella* spp., including *B. bacilliformis*, are able to survive in blood stored for long periods of time^{6,7}. Moreover, in animal studies, infections have been induced by *Bartonella* spp.-infected blood⁸. Thus, it is known that there is a risk of transmitting members of the *Bartonella* genus by transfusion.

Case report

A 47-year old male attended the outpatient clinic of the Hospital of Cajamarca, northern Peru, with anaemia, headache and dyspnoea, which had evolved over approximately 3 months. The patient had been diagnosed 2 years previously with chronic myeloid leukaemia and had been treated with imatinib 400 mg/day for the first year, after which the patient discontinued treatment.

Physical examination revealed pallor and splenomegaly, but not jaundice. Blood analysis showed a haematocrit of 10%, a haemoglobin of 3.3 g/dL, white blood cell count of $5.0 \times 10^4/\text{mm}^3$ and a platelet count of $3.4 \times 10^4/\text{mm}^3$; additionally bone marrow analysis showed the presence of myeloid blasts (18%) and basophils (21%), all findings compatible with chronic myeloid leukaemia in accelerated phase. The patient received several packs of red blood cells (RBC) and

platelet transfusion, and the imatinib treatment was restarted (600 mg/day). The patient was eventually discharged with a haemoglobin of 11.6 g/dL, total bilirubin of 0.8 mg/dL, and conjugated bilirubin of 0.4 mg/dL. He was periodically controlled during the subsequent months and given various RBC and platelet transfusions (Figure 1).

On day 117 after his first visit, the patient attended the Emergency Department again, presenting with anaemia, fever (38.8 °C), acute bloody diarrhoea, pallor, jaundice and splenomegaly, being treated with ceftriaxone (2 g/day) and additional RBC and platelet transfusions.

Five days later (day 122), he developed additional anasarca and dyspnoea as well as pulmonary crackles, alanine transaminase and aspartate transaminase levels of 8 U/mL and 15 U/mL respectively and hyperbilirubinemia (total bilirubin: 6 mg/dL; conjugated bilirubin: 4.6 mg/dL) which suggested the need to withdraw the imatinib treatment. The anaemia appeared to be haemolytic in nature considering the refractoriness to blood transfusions and the concomitant rise in bilirubin levels. Therefore, a direct Coombs test was carried out (which was negative), a thin blood film was examined, polymerase chain reaction analysis (PCR) was performed and blood was cultured for *B. bacilliformis*⁹. The PCR results (*data not shown*) confirmed the presence of *B. bacilliformis*, and the patient was then diagnosed with Oroya fever. The antibiotic treatment was changed to parenteral ceftazidime (2 g/8 h) plus ciprofloxacin (200 mg/12 h)^{10,11}. The patient was discharged on day 136 after being referred to a reference hospital for further chemotherapy of the chronic myeloid leukemia (Table I, Figure 1).

Concomitantly, a collaborative study between the Peruvian University of Applied Sciences (UPC) in Lima and the Hospital of Cajamarca was underway to determine the prevalence of bacterial pathogens not included in routine blood bank determinations, such as *B. bacilliformis*, amongst blood donors^{12,13}. Within this study, after obtaining informed consent, 3 mL of whole blood were taken from blood donations prior to these being processed to obtain any blood component or derivative. In all cases, blood samples were stored at 4 °C

Table I - Clinical data during the patient's admission for Oroya fever.

Date (dd/mm/yyyy)	Day ¹	WBC (×mm ³)	RBC (×10 ⁶)	Ht	Hb	Plt (×mm ³)	Indirect bilirubin (mg/dL)	Total bilirubin (mg/dL)	Coombs ²
07/05/2014	117	8,600	1.4	14	-	12,000	-	-	-
09/05/2014	119	8,100	2.6	22	-	10,000	3.3	-	-
11/05/2014	121	-	-	14	-	-	-	-	-
12/05/2014	122	4,200	1.3	12	4.0	-	4.6	6.0	Negative
13/05/2014	123	-	-	10	3.9	7,000	-	-	-
14/05/2014	124	-	-	-	5,3	-	-	-	-
16/05/2014	126	-	-	20	6.5	5,000	-	-	-
17/05/2014	127	3,400	2.5	22	7.3	10,000	-	-	-
18/05/2014	128	-	-	24	7.8	15,000	4.7	-	-
20/05/2014	130	-	-	32	10.7	5,000	4.7	9.0	-
21/05/2014	131	-	-	-	9.8	8,000	-	-	-
22/05/2014	132	-	-	-	10.7	-	4.0	6.7	-
23/05/2014	133	-	-	30	9.8	10,000	-	-	-
25/05/2014	135	-	-	27	9.0	5,000	2.1	3.5	-
26/05/2014	136	1,800	3.1	27	-	15,000	-	-	-

¹Day after admission; ²Direct Coombs' test; WBC: white blood cells; RBC: red blood cells; Ht: haematocrit; Hb: haemoglobin; Plt: platelets.

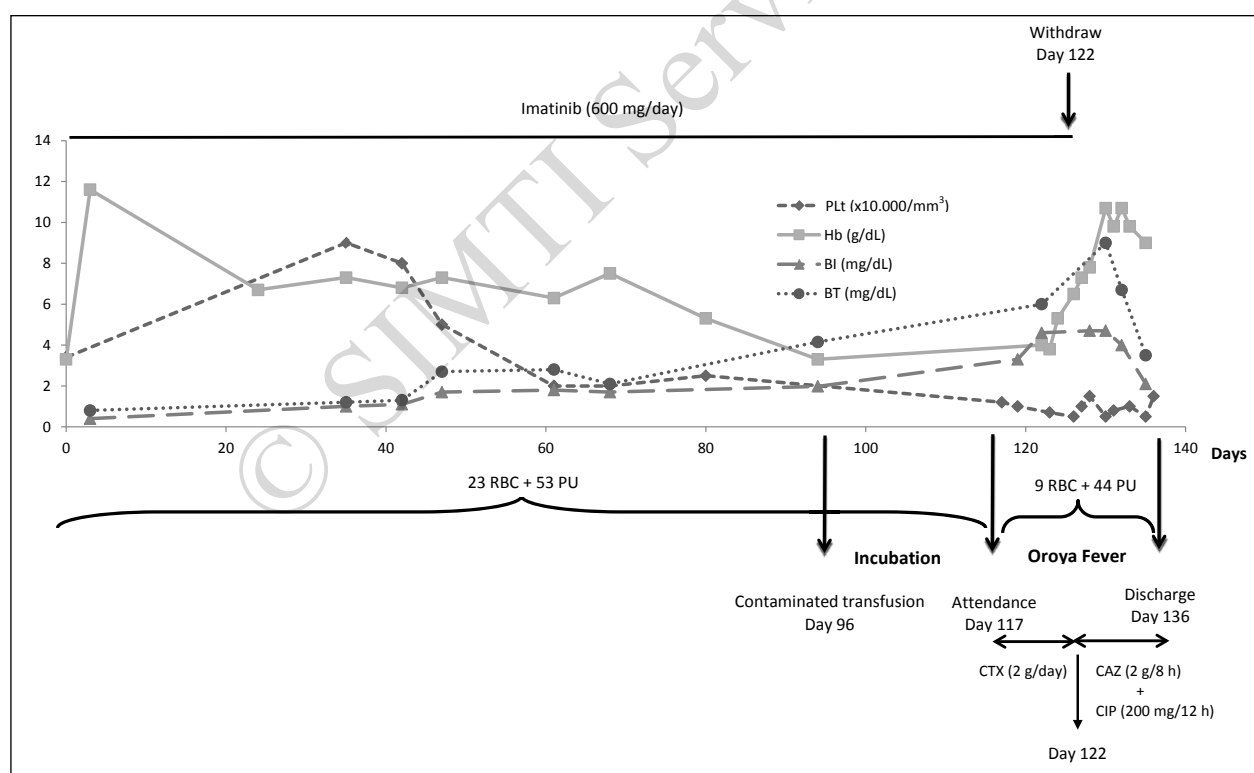


Figure 1 - The patient's clinical course.

No units are presented in the Y axis; the units corresponding to each parameter are indicated in the legend.

Arrows indicate the contaminated transfusion, the admission due to Oroya fever and the subsequent discharge.

The markers in the lines indicate the days on which the specific parameter was measured.

RBC: red blood cells (packs transfused); PU: platelets units transfused; Hb: haemoglobin levels; BI: indirect bilirubin; BT: total bilirubin; Plt: platelets; CTX: cefotaxime; CAZ: ceftazidime; CIP: ciprofloxacin.

for a maximum of 1 week in the Hospital of Cajamarca prior to being sent to UPC.

This study revealed the presence of *B. bacilliformis* in a blood donation from which platelets were obtained. These platelets were transfused to the above described patient 21 days prior (day 96) to admission to hospital with symptoms of Oroya fever.

Discussion

Although blood transfusion is considered to be one of the mechanisms of transmitting *B. bacilliformis*, to the best of our knowledge such transmission has only been described once¹⁴. In 1972 it was reported that a neonate died of Oroya fever after a blood transfusion from a family member living in an area in which *B. bacilliformis* was endemic. Although vertical transmission has been proposed⁵, the mother did not have a previous *Bartonella* infection¹⁴. With regards to transfusion-related transmission of other *Bartonella* spp., it was suspected that *B. henselae* had been transmitted by transfusion, but the fact was not firmly established¹⁵. Similarly, Scolfaro *et al.*¹⁶ reported possible transmission of *B. henselae* by a transplant, although natural infection could not be ruled out.

Although *B. bacilliformis* infects RBC, the presence of this bacterium in a platelet concentrate is not surprising, because of the presence of bacteria outside of erythrocytes, and because the risk of transmitting bacterial infections by platelet concentrate transfusion is higher than that associated with the transfusion of RBC or other blood components. Indeed, platelet transfusions account for 87% of all blood transfusion-related bacterial infections¹⁷.

In the present case, possible natural infection by a sand-fly bite cannot be ruled out, as the patient lived close to endemic areas. Although to the best of our knowledge the patient had not travelled out of Cajamarca city and thus had not been exposed to endemic areas, we want to be cautious on this point and consider that the patient may not have mentioned possible short journeys to nearby areas when interviewed. However, the facts that a platelet transfusion was contaminated with this microorganism and that the time elapsed from the transfusion to the emergency room visit was compatible with the incubation time¹¹ strongly suggest transfusion-related transmission.

Prior to the contaminated transfusion, the patient had marked decreases in platelet count (day 40 onwards) and haemoglobin concentration (between days 80 [5.3 g/dL] and 94 [3.3 g/dL]). Although these facts might support a natural *B. bacilliformis* infection established before the contaminated platelet transfusion, the general health status of the patient must be taken into account in addition to the fact that alterations in

RBC count (and thus in haemoglobin) and/or platelet count are common in the accelerated phase of chronic myeloid leukaemia. Additionally, the rise in bilirubin concentration occurred after the aforementioned transfusion, suggesting that the haemolytic anaemia may have arisen as a consequence of it.

Peruvian national legislation related to blood banks includes the obligation to screen for the presence of human immunodeficiency virus, human T-lymphotropic viruses 1 and 2, hepatitis B and C viruses, *Trypanosoma cruzi* and *Treponema pallidum*, while detection of other pathogens such as *B. bacilliformis* or *Plasmodium* spp. is only considered in Peruvian blood banks in endemic areas^{12,13}.

Carrion's disease is not distributed uniformly in the Cajamarca Department, being restricted to specific endemic areas, because of the Department's size (more than 35,000 km²) and great climatic diversities. The Hospital of Cajamarca is located in the capital of the Cajamarca Department, an urban area considered free of *B. bacilliformis*. Consequently routine screening in the hospital only tests for the seven pathogens specified in Peruvian national legislation^{12,13}. Thus, in order to avoid transfusion risks, potential donors in the blood bank of the Hospital of Cajamarca are interviewed and those living in specific, endemic areas are not accepted as donors, because of the difficulties in making a correct diagnosis^{3,9}.

B. bacilliformis is a fastidious, slow-growing microorganism, requiring blood-enriched media, a temperature of 28-30 °C, and 5% CO₂ in order to grow⁹: bacterial cultures are not, therefore, useful for diagnosing *B. bacilliformis* infection, as in the present case, in which no positive cultures were obtained after 5 months. In endemic areas techniques such as microscopy are often used; this has a diagnostic sensitivity ranging from 24 to 36% in patients with Oroya fever³, but has little utility in the case of asymptomatic carriers because of the low bacterial burden¹⁸. Molecular tools, such as PCR, which are often not available in endemic areas, provide better results but seem to have only limited value for detecting asymptomatic carriers^{9,19}. There is a need for techniques with greater sensitivity, which could be used routinely in blood banks in endemic areas.

We found *B. bacilliformis* in a transfusion sample, thus demonstrating the potential risk of transfusion-related transmission, and highlighting the fact that a contaminated transfusion may be performed in a non-endemic area. This may be related to human travel, with inhabitants from endemic areas settling in non-endemic areas or inhabitants from non-endemic areas travelling to endemic ones. Such travel may facilitate the development of asymptomatic, *B. bacilliformis* carriers as blood donors and it should be taken into account that there are no data regarding the

duration of the status of a healthy carrier. In addition, due to the continuous movement of people and trade between the city and endemic areas, the introduction of vectors into the city of Cajamarca, a non-endemic area, cannot be excluded. This fact might result in the development of vector-borne diseases, as has been described in other areas²⁰.

In summary, the present report describes the presence of *B. bacilliformis* in a blood bank sample and the probable association between a blood transfusion and the development of Oroya fever, supporting the need for a sensitive detection technique that could be implemented in blood banks.

Acknowledgements

This study was supported by internal funds from the *Universidad Peruana de Ciencias Aplicadas* (Lima, Peru) (JdV), by a grant of the *Instituto de Salud Carlos III* - Spain (PI11/00983), by UBS Optimus Foundation (JR, JdV) and by *Generalitat de Catalunya, Departament d'Universitats, Recerca i Societat de la Informació* (2014 SGR 26) (JR).

MJP has a post-doctoral fellowship from CONCYTEC/FONDECYT. JR has a fellowship from the I3 programme of the ISCIII (grant number: CES11/012).

We thanks Donna Pringle and Ralph H. O'Dwyer for language editing.

Authorship contributions

NU, PL, MJP, JR and JdV designed the study. MJP performed the experiments. PL, JS and NU gathered clinical and epidemiological data. MJP, JR and JdV analysed the data and wrote the manuscript. All the Authors read and approved the final version of the manuscript.

Keywords: Carrion's disease, *Bartonella bacilliformis*, blood transfusion, transfusion-transmitted disease.

The Authors declare no conflicts of interest.

References

- Maguiña C, Guerra H, Ventosilla P. Bartonellosis. Clin Dermatol 2009; **27**: 271-80.
- Pachas PE. *Enfermedad de Carrion (Bartonellosis) en el Perú*. Lima: Ministerio de Salud; 2001.
- Sanchez Clemente N, Ugarte-Gil CA, Solórzano N, et al. *Bartonella bacilliformis*: a systematic review of the literature to guide the research agenda for elimination. PLoS Negl Trop Dis 2012; **6**: e1819.
- Herrer A. Carrion's disease. Presence of *Bartonella bacilliformis* in the peripheral blood of patients with the benign form. Am J Trop Med Hyg 1953; **2**: 645-9.
- Tuya XL, Escalante-Kanashiro R, Tinco C, et al. Possible vertical transmission of *Bartonella bacilliformis*. Am J Trop Med Hyg 2015; **92**: 126-8.
- Magalhães RF, Pitassi LH, Salvadego M, et al. *Bartonella henselae* survives after the storage period of red blood cell units: is it transmissible by transfusion? Transfus Med 2008; **18**: 287-91.
- Ruiz J, Silva W, Pons MJ, et al. Long time survival of *Bartonella bacilliformis* in blood stored at 4 °C. Blood Transfus 2012; **10**: 563-4.
- Kordick DL, Brown TT, Shin K, Breitschwerdt EB. Clinical and pathologic evaluation of chronic *Bartonella henselae* or *Bartonella clarridgeiae* infection in cats. J Clin Microbiol 1999; **37**: 1536-47.
- del Valle Mendoza J, Silva Caso W, Tinco Valdez C, et al. Diagnosis of Carrion's disease by direct blood PCR in thin blood smear negative samples. PLoS One 2014; **9**: e92283.
- Freifeld AG, Bow EJ, Sepkowitz KA, et al. Clinical practice guideline for the use of antimicrobial agents in neutropenic patients with cancer: 2010 update by the Infectious Diseases Society of America. Clin Infect Dis 2011; **52**: e56-93.
- Tarazona A, Maguiña C, Lopez de Guimaraes D, et al. Terapia antibiótica para el manejo de la Bartonelosis o Enfermedad de Carrion en el Perú. Rev Peru Med Exp Salud Publ 2006; **23**: 188-200.
- Ministerio de Salud. Doctrina, normas y procedimientos del programa nacional de hemoterapia y bancos de sangre. Ministerio de Salud, Lima (Peru). 1998. Available at: <http://bvs.minsa.gob.pe/local/minsa/1894.PDF>. Accessed on 08/02/2015.
- Ministerio de Salud. Sistema de gestión de la calidad del Pronahebas. Manual de Calidad. Ministerio de Salud, Lima (Peru). 2004. Available at: <http://www.minsa.gob.pe/portada/Especiales/2010/donasangre/Archivos/bases/RM%20614-2004%20%20gestion%20de%20la%20calidad.pdf>. Accessed on 08/02/2015.
- Maguiña Vargas C. *Bartonellosis o Enfermedad de Carrion. Nuevos Aspectos de una Vieja Enfermedad*. Lima: A.F.A. Editores Importadores; 1998.
- Magalhães RF, Urso Pitassi LH, Lania BG, et al. Bartonellosis as cause of death after red blood cell unit transfusion. Ultrastruct Pathol 2009; **33**: 151-4.
- Scolfaro C, Mignone F, Gennari F, et al. Possible donor-recipient bartonellosis transmission in a pediatric liver transplant. Transpl Infect Dis 2008; **10**: 431-3.
- Lafeuillade B, Eb F, Ounnoughene N, et al. Residual risk and retrospective analysis of transfusion-transmitted bacterial infection reported by the French National Hemovigilance Network from 2000 to 2008. Transfusion 2015; **55**: 636-46.
- Chamberlin J, Laughlin LW, Romero S, et al. Epidemiology of endemic *Bartonella bacilliformis*: a prospective cohort study in a Peruvian mountain valley community. J Infect Dis 2002; **186**: 983-90.
- Gomes C, Silva W, Tinco C, et al. Evaluation of three PCR schemes for detection of *Bartonella bacilliformis* in blood samples: sensitivity, specificity and applicability. Int J Infect Dis 2014; **21** (Suppl 1): 367.
- Medlock JM, Hansford KM, Schaffner F, et al. A review of the invasive mosquitoes in Europe: ecology, public health risks, and control options. Vector Borne Zoonotic Dis 2012; **12**: 435-47.

Arrived: 10 February 2015 - Revision accepted: 7 July 2015

Correspondence: Joaquim Ruiz
 CRESIB
 Ed. CEK, pl1
 C/ Rosselló 149-153
 08036 Barcelona, Spain
 e-mail: joruiz@clinic.ub.es