


## Intravenous immunoglobulin–induced acute thrombocytopenia

Anna Gurevich-Shapiro <sup>1,2,4</sup> Lilach Bonstein,<sup>3</sup> Galia Spectre,<sup>2,4</sup> Nardeen Atweh,<sup>3</sup>  
Tsipora Gruenewal,<sup>2</sup> Michael Shapiro,<sup>4</sup> Boaz Tadmor,<sup>2,4</sup> and Pia Raanani<sup>2,4</sup>

**BACKGROUND:** Intravenous immunoglobulin (IVIG) has known efficacy in various hematologic conditions, including immune thrombocytopenic purpura.

**STUDY DESIGN AND METHODS:** We present the clinical course of a patient with splenic marginal zone lymphoma, who developed acute thrombocytopenia on three consecutive episodes, with nadir counts of  $27 \times 10^9$ ,  $50 \times 10^9$ , and  $9 \times 10^9$ /L, upon administration of Intratect IVIG for hypogammaglobulinemia. An immunofluorescence test applying flow cytometry and monoclonal antibody immobilization of platelet antigens (MAIPA) assay were used to evaluate the reaction between IgG present in the IVIG preparations and the patient's or healthy donors' platelets (PLTs).

**RESULTS:** A strong direct binding reaction was observed between the patient's PLTs and Intratect IgG using both methods. A similar reaction failed to materialize with controls. Binding was not antigen specific according to MAIPA.

**CONCLUSIONS:** This is the first reported case of thrombocytopenia as a possible adverse effect of IVIG.

**ABBREVIATIONS:** EBV = Epstein-Barr virus; MAIPA = monoclonal antibody immobilization of platelet antigens; PIFT = platelet immunofluorescence test; PRP = platelet-rich plasma.

From the <sup>1</sup>Internal Medicine H, Tel Aviv Sourasky Medical Center, Tel Aviv, Israel; the <sup>2</sup>Institute of Hematology, Davidoff Cancer Center, Beilinson Hospital, Rabin Medical Center, Petah-Tiqwa, Israel; the <sup>3</sup>Platelet Immunology Laboratory, Rambam Medical Center, Haifa, Israel; and the <sup>4</sup>Sackler School of Medicine, Tel Aviv University, Ramat-Aviv, Israel.

*Address reprint requests to:* Anna Gurevich-Shapiro, MD, MPhil, Internal Medicine H, Tel Aviv Sourasky Medical Center, Tel Aviv, Israel; e-mail: anna.gur@gmail.com.

Received for publication August 3, 2017; revision received October 9, 2017; and accepted October 18, 2017.

doi:10.1111/trf.14419

© 2017 AABB

TRANSFUSION 2018;58:493–497

Formulations of intravenous immunoglobulins (IVIGs) are pooled blood products acquired from multiple donors.<sup>1</sup> IVIG was first used three decades ago in the treatment of primary and secondary immunodeficiency syndromes. The implementation of IVIG has since expanded into other hematologic and nonhematologic indications, with developments in the mode of transfusion and the administered doses.<sup>2</sup>

The main component of IVIG formulations is immunoglobulin (Ig)G (90%-98%). The precise titer of antibodies varies between IVIG preparations.<sup>3</sup> All products also contain IgA and IgM antibodies in varying concentrations, T-helper type 2 (Th2), cytokines, and cytokine antagonists.<sup>4</sup> IgG is thought to induce both a proinflammatory and an anti-inflammatory effect on the immune system, depending on the dosage.<sup>5</sup>

IVIG is known for its favorable tolerability profile. The most common adverse events are transfusion related and include malaise, flushing, and chills with a transfusion rate of 5% to 15%.<sup>6</sup> Several hematologic complications have been reported, namely, hemolysis, leukopenia, neutropenia, monocytopenia, disseminated intravascular coagulation, and thrombosis.<sup>7-10</sup> Most of these phenomena are transient and self-limited, although hemolysis might result in serious complications. Hemolysis is attributed to direct antibody-mediated attack by anti-A and anti-B present in the pooled plasma.<sup>3,11</sup> The pathophysiology for the other cytopenias remains unclear.

To date, no reports exist of thrombocytopenia as a possible adverse effect of IVIG. Conversely, IVIG is an established treatment for immune thrombocytopenic purpura. Herein, we present a case of thrombocytopenia after the administration of the Intratect IVIG preparation (manufactured by BioTest) in a patient with hypogammaglobulinemia and recurrent infections secondary to lymphoma. The laboratory workup as well as a discussion of the implications and possible mechanisms are presented.

### CASE REPORT

#### Medical background

The patient is an 80-year-old female with a medical history significant for hyperlipidemia, hypothyroidism, osteoarthritis,

and lumbar spine stenosis. She underwent a lumpectomy followed by radiation for carcinoma of the breast in 1999. Regular medications included aspirin, bisoprolol, atorvastatin, ezetimibe, magnesium citrate, and L-thyroxine.

In 2007, the patient was diagnosed with splenic marginal zone lymphoma with villous lymphocytes while she underwent a thorough investigation for a suspected autoimmune disease manifested by arthralgia, dyspnea, and thyroiditis. Laboratory tests at the time demonstrated elevated inflammatory markers, a positive anti-nuclear antibody and a low Complement Component 4. Peripheral blood smear demonstrated lymphocytosis and immunophenotype was positive for CD19, CD 20, CD22, CD11c, FMC7, IgM, and IgD. A marrow biopsy confirmed the diagnosis of splenic marginal zone lymphoma. In 2008 the patient developed B symptoms, which prompted the administration of five courses of rituximab. Complete remission was achieved, confirmed by a marrow biopsy.

Corticosteroids were administered since 2007 for pneumonitis confirmed on a lung biopsy. Attempts to reduce the dosage of corticosteroids resulted in worsening of the symptoms, which finally led to introduction of azathioprine as a steroid-sparing treatment.

In early 2008, the patient had recurrent lung infections, requiring hospitalization. Her test results demonstrated persistent hypogammaglobulinemia. Omrigam IVIG (Omrix Biopharmaceuticals; 30 g/month, 0.4 g/kg) was first introduced in March 2008. Omrigam was replaced with Sandoglobulin (manufactured by CSL Behring) in October 2008 due to a suspected thromboembolic adverse event.

At the beginning of 2012, a gradual decline in the white blood cell count was noticed, particularly of the neutrophil lineage, which led to the discontinuation of azathioprine. A routine chest x-ray carried out immediately before discontinuation of azathioprine showed bilateral pulmonary masses. This finding was confirmed by PET-CT. A second lung biopsy demonstrated an Epstein-Barr virus (EBV)-positive B-cell lymphoproliferative disorder with Hodgkin-like cells. The large atypical cells were positive for CD30, CD15 (focal/weak), CD20, CD79a, EBER-*ish*. Plasma EBV DNA level was 345,000 EBV/mL.

Due to EBV positivity of the cells in a setting of immunosuppression (prolonged treatment with azathioprine), the patient was diagnosed as suffering from posttransplantation lymphoproliferative disorder. The treatment regimen included four courses of rituximab monotherapy. However, a PET-CT scan after the fourth cycle did not show a response and thus six courses of R-CHOP (cyclophosphamide, adriamycin, vincristine, prednisone) treatment ensued. Complete remission was then achieved without signs of relapse until April 2017.<sup>12</sup>

### IVIG-induced thrombocytopenia

The patient received monthly IVIG transfusions (a dosage of 30 g, 0.4 g/kg) throughout 2008 to 2015, as prophylaxis

against recurrent respiratory infections and hypogammaglobulinemia. IVIG administration was complicated by thrombocytopenia on three documented episodes (Fig. 1).

The first episode took place in December 2014, while the patient was transfused with the fourth dose of Intratect. The transfusion was accompanied by chills, promoting performance of a complete blood count. The pre-IVIG transfusion platelet (PLT) count, which was  $177 \times 10^9/L$ , decreased the next day to  $27 \times 10^9/L$ . Two days posttransfusion the PLT count reached  $45 \times 10^9/L$ . The next available PLT count of  $158 \times 10^9/L$  was recorded 1 month later. No bleeding episodes were documented.

A second episode of thrombocytopenia was noted on the consecutive month, with a pre-Intratect IVIG transfusion level of  $158 \times 10^9/L$  and a 2-day posttransfusion count of  $50 \times 10^9/L$ . No allergic reactions were reported. Six days after IVIG administration, the PLT count reached  $146 \times 10^9/L$ , and 1 week later stabilized at  $187 \times 10^9/L$ .

The third episode occurred 2 months later and resulted in a decrease from a PLT count of  $160 \times 10^9$  to  $13 \times 10^9/L$  5 hours postadministration of Intratect, decreasing further to  $9 \times 10^9/L$  8 hours posttransfusion. Of note, administration of IVIG was interrupted due to dyspnea and chills, which responded to a single dose of antihistamines and corticosteroids. An investigation for the cause of thrombocytopenia was performed and demonstrated: normal values of prothrombin time (10.6 sec), partial thromboplastin time (29 sec), and fibrinogen (399 mg/dL). A direct antiglobulin test was negative. Haptoglobin was within the normal range (144 mg/dL). Hemoglobin was first unaffected, with a decrease of 1.6 g 24 hours posttransfusion from 12.2 to 10.6 g/dL. Eosinophil count was normal.

No signs of bleeding appeared during the 24-hour hospital stay. The patient was treated with six random-donor PLT units due to a PLT count of less than  $10 \times 10^9/L$  and an increased risk for bleeding as a result of chronic treatment with aspirin. PLT count began steadily recovering 24 hours posttransfusion, reaching  $44 \times 10^9$  and  $51 \times 10^9/L$  on the following day. By 6 days posttransfusion the PLT count has reached near-normal levels of  $146 \times 10^9/L$ . IVIG treatment was discontinued permanently.

## MATERIALS AND METHODS

Drug-dependent antibodies directed at PLTs were evaluated by two procedures as follows: a direct and indirect immunofluorescence test (PLT immunofluorescence test [PIFT]), using a fluorescein isothiocyanate (FITC)-conjugated anti-human IgG and measured by flow cytometry and monoclonal antibody immobilization of PLT antigen (MAIPA) assay. Each was conducted twice in the presence and absence of three different IVIG preparations, namely, Intratect, Omrigam, and Gammaplex (Bio Products Laboratory). The reaction was compared with healthy O-typed controls' PLTs and sera. The patient's serum was drawn

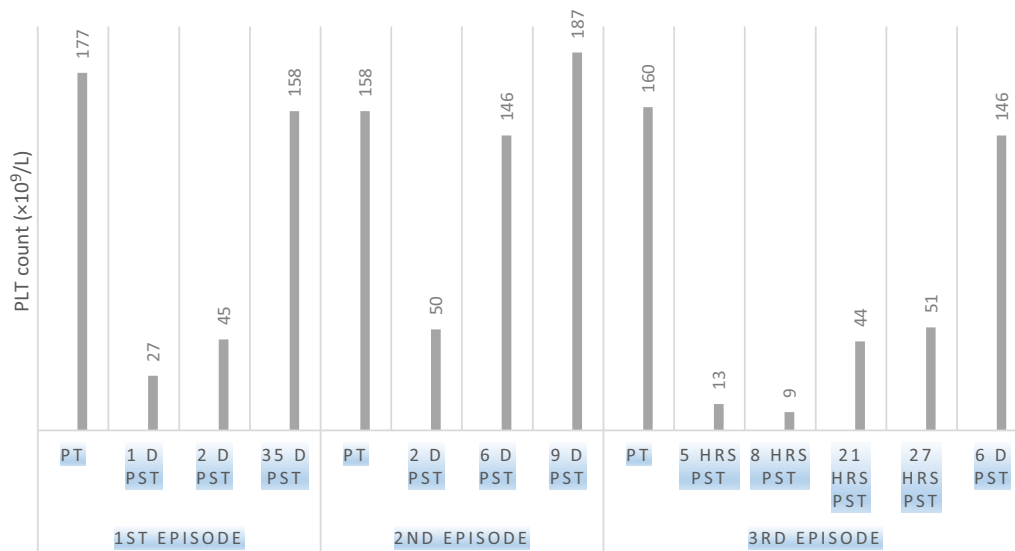


Fig. 1. PLT counts after Intratect IVIG administration. [Color figure can be viewed at [wileyonlinelibrary.com](http://wileyonlinelibrary.com)]

for examination 2 weeks after the last reported episode of thrombocytopenia.

**PIFT**

PIFT was used to screen for PLT-associated antibodies (direct PIFT) and anti-PLT antibodies in patient’s plasma and/or IVIG (indirect PIFT), as previously described.<sup>13,14</sup> Patient’s PLTs were prepared from PLT-rich plasma (PRP) by centrifugation of 6 mL of patient’s anticoagulated whole blood (in EDTA) at 800 × g for 20 minutes, washed twice with normal saline at 13,000 × g for 5 minutes, and resuspended in saline to a final concentration of 100 × 10<sup>6</sup> cells/mL. Control PLTs were obtained from a pool of 1.2 mL of PRP from three group O random PLT units (200 μL/unit). PRP was washed twice with normal saline at 13,000 × g for 5 minutes. PLT pellet was then resuspended in saline to a final concentration of 100 × 10<sup>6</sup> cells/mL.

For both assays, 60 μL of patient’s serum and or IVIG were added to the PLT pellet, incubated at 37°C for 40 minutes, and then washed three times with 150 μL of saline at 13,000 × g for 5 minutes. Cells were then resuspended in 60 μL of FITC-conjugated goat anti-human IgG (DAKO) and incubated at room temperature in the dark for 20 minutes. Results were obtained using a flow cytometer (FACSCalibur, Becton Dickinson) and analyzed by computer software (FlowJo, FlowJo, LLC).

**MAIPA assay**

The MAIPA assay was carried out as described<sup>14,15</sup> with minor modifications: 100 μL of PLT suspension (200 × 10<sup>9</sup>/L PLTs) from a patient and a mix of six healthy PLTs donors were incubated with 50 μL of the patient’s serum and/or IVIG, washed three times with PBS-EDTA, and

then allowed to react with the following monoclonal antibodies (MoAbs): GPIIbIIIa-CD41 (Clone P2, Immunotech), GPIaIIa-CD49b (Clone Gi9, Immunotech), GPIbIX-CD42b (Clone SZ1, Immunotech), and GPIbIX-CD42a (Clone SZ1, Immunotech).

A lysis buffer (2.5 mL NP-40-Igepal CA-630 + 25 mg of leupeptin 50 μg/mL) containing Triton X-100 was then used and the immune complexes were incubated in a microplate coated with a goat anti-mouse antibody (Jackson ImmunoResearch). Positive reactions were detected by the use of horseradish peroxidase-labeled goat anti-human IgG (Jackson ImmunoResearch) and *o*-phenylenediamine (DakoCytomation) as its substrate. Results (optical density [OD]) were obtained at 492 and 620 nm using an ELISA reader 510 (Organon Teknika).

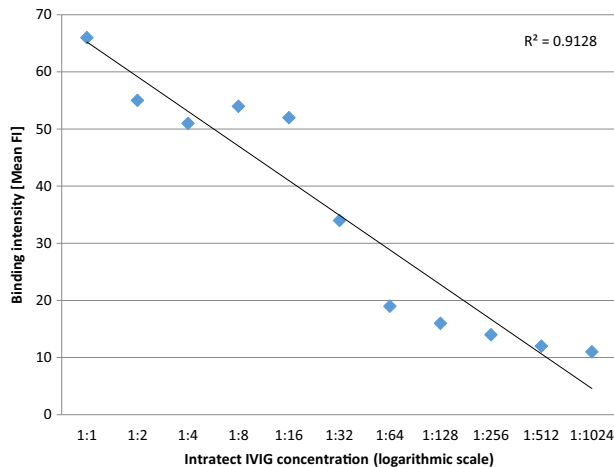
**RESULTS**

**PIFT**

The PIFT method demonstrated a strong positive binding reaction between Intratect and the patient’s PLTs (67 IF: where negative control, 8; positive control, 55). Binding intensity was directly correlated with the concentration of IVIG (Fig. 2). Control PLTs showed negative results when incubated with Intratect with or without the patient’s serum (10-11 IF).

A further comparison was performed to determine whether the effect is a class effect, characteristic of all IVIG preparations, or rather specific to the particular brand of Intratect. With a concentration of 50 mg/mL of each preparation, Gammaplex and Omrigam were separately introduced in addition to Intratect as the reagents.

Intratect continued to demonstrate a positive reaction with the patient’s PLTs and a negative reaction with



**Fig. 2. Correlation of binding intensity to Intratect concentration.** [Color figure can be viewed at [wileyonlinelibrary.com](http://wileyonlinelibrary.com)]

control PLTs. A strong positive reaction was also observed between the patient's PLTs and Gammaplex and Omrigam. However, in the case of the two added reagents, control PLTs yielded a positive reaction, although weaker compared to the reaction with the patient's serum.

### MAIPA

Since Intratect yielded a reaction *in vivo* as well as *in vitro*, a further examination was performed to characterize the binding of Intratect to the patient's PLTs. A direct MAIPA assay was performed. Intratect was incubated with the PLTs after incubation with MoAbs against PLT glycoproteins GPIIb/IIIa, GPIa/IIa, and GPIb/IX. Intratect resulted in a twofold stronger signal with patient's PLTs than with O-typed controls on GPIIb/IIIa and GPIa/IIa (Table 1).

## DISCUSSION

We described a patient with hypogammaglobulinemia secondary to lymphoma, who repeatedly developed thrombocytopenia after the administration of Intratect IVIG. To our knowledge, this is the first reported case of thrombocytopenia induced by IVIG.

The laboratory results demonstrated a dose-dependent binding pattern of IgG present in Intratect to the patient's PLTs. Control PLTs failed to demonstrate a similar reaction. No antigen-specific binding was characterized.

We suggest that the formed IgG-PLT complexes were then removed by the reticuloendothelial system, similarly to the pathogenesis observed in immune thrombocytopenic purpura.<sup>16</sup> Since the antibodies were from an extrinsic source (the IVIG solution), the decrease in PLT counts was self-limiting and transient.

It is unclear, however, which feature of the patient's PLTs caused the IgG content of the preparations to

**TABLE 1. MAIPA results of IVIG binding to patient's and controls' PLTs using Intratect [OD]**

PLT GP	Patient's PLTs	Controls' PLTs
GPIIb/IIIa (CD41)	0.215	0.121
GPIa/IIa (CD49)	0.167	0.081
GPIb/IX (CD42a)	0.091	0.062

Negative control, 0.005; positive control, 1.084.

recognize her PLTs to a higher degree than controls. Several characteristics in the patient's medical history might have contributed to the extent of the reaction, namely, a history of lymphoproliferative disorders, which is a well-known predisposition to immune thrombocytopenic purpura.<sup>17</sup> Our patient's disease was characterized by an unusual array of autoimmune phenomena, including pneumonitis and joint pain. Autoimmune and inflammatory states were previously noted to contribute to a higher incidence of hematologic adverse events resulting from IVIG.<sup>18,19</sup> Cytokine release syndrome, in particular, has been described by our group as a contributing factor to thrombocytopenia induced by rituximab.<sup>20</sup>

Moreover, clinical signs of hypersensitivity, documented at the time of the PLTs' nadir, in combination with the progressive amplification of thrombocytopenia in reaction to Intratect, suggest a process of "sensitization," characteristic of hypersensitivity reactions (Type II or III). The lack of eosinophilia at the recorded thrombocytopenia episodes does not support this hypothesis.

Another possible explanation includes concurrent medications used regularly by the patient, which could promote IgG binding to the patient's PLTs.<sup>18</sup> Drug-induced thrombocytopenia is generally caused by an antibody presenting only in the presence of a specific drug. In this case, however, the IVIG exhibited direct IgG binding with the patient's PLTs. In conclusion, we suggest thrombocytopenia as a possible and rare side effect of IVIG.

### CONFLICT OF INTEREST

The authors have disclosed no conflicts of interest.

## REFERENCES

- Berard R, Whittemore B, Scuccimarri R. Hemolytic anemia following intravenous immunoglobulin therapy in patients treated for Kawasaki disease: a report of 4 cases. *Pediatr Rheumatol Online J* 2012;10:10.
- Chérin P, Cabane J. Relevant criteria for selecting an intravenous immunoglobulin preparation for clinical use. *Biodrugs* 2010;24:211-23.
- Padmore RF. Hemolysis upon intravenous immunoglobulin transfusion. *Transfus Apher Sci* 2012;46:93-6.
- Hartung HP. Advances in the understanding of the mechanism of action of IVIG. *J Neurol* 2008;255:3-6.

5. Lux A, Aschermann S, Biburger M, et al. The pro and anti-inflammatory activities of immunoglobulin G. *Ann Rheum Dis* 2010;69:i92-i6.
6. Bonilla FA. Intravenous immunoglobulin: adverse reactions and management. *J Allergy Clin Immunol* 2008;122:1238-9.
7. Späth PJ, Granata G, La Marra F, et al. On the dark side of therapies with immunoglobulin concentrates: the adverse events. *Front Immunol* 2015;6:11.
8. Matsuda M, Hosoda W, Sekijima Y, et al. Neutropenia as a complication of high-dose intravenous immunoglobulin therapy in adult patients with neuroimmunologic disorders. *Clin Neuropharmacol* 2003;26:306-11.
9. Baxley A, Akhtari M. Hematologic toxicities associated with intravenous immunoglobulin therapy. *Int Immunopharmacol* 2011;11:1663-7.
10. von Gunten S, Schaub A, Vogel M, et al. Immunologic and functional evidence for anti-Siglec-9 autoantibodies in intravenous immunoglobulin preparations. *Blood* 2006;108:4255-9.
11. Alhumaidan H, Sweeney J. Intravascular hemolysis from liquid IVIG may be caused by anti A, B antibody. *Transfusion* 2012;52:178A.
12. Trappe R, Oertel S, Leblond V, et al. Sequential treatment with rituximab followed by CHOP chemotherapy in adult B-cell post-transplant lymphoproliferative disorder (PTLD): the prospective international multicentre phase 2 PTL-D-1 trial. *Lancet Oncol* 2012;13:196-206.
13. Heikal NM, Smock KJ. Laboratory testing for platelet antibodies. *Am J Hematol* 2013;88:818-21.
14. Loerbroks A, Weigl M, Li J, et al. Effort-reward imbalance and perceived quality of patient care: a cross-sectional study among physicians in Germany. *BMC Public Health* 2016;16:342.
15. Kiefel V, Santoso S, Weisheit M, et al. Monoclonal antibody-specific immobilization of platelet antigens (MAIPA): a new tool for the identification of platelet-reactive antibodies. *Blood* 1987;70:1722-6.
16. Johnsen J. Pathogenesis in immune thrombocytopenia: new insights. *Hematology Am Soc Hematol Educ Program* 2012;2012:306-12.
17. Kaden BR, Rosse WF, Hauch TW. Immune thrombocytopenia in lymphoproliferative diseases. *Blood* 1979;53:545-51.
18. Berg R, Jacob D, Fuellenhals E. Hemolytic events after the administration of lyophilized versus liquid immune globulin: an analysis of a single manufacturer's safety database. *Transfusion* 2015;55:1847-54.
19. Pendergrast J, Willie-Ramharack K, Sampson L, et al. The role of inflammation in intravenous immune globulin-mediated hemolysis. *Transfusion* 2015;55:S65-73.
20. Ram R, Bonstein L, Gafter-Gvili A, et al. Rituximab-associated acute thrombocytopenia: an under-diagnosed phenomenon. *Am J Hematol* 2009;84:247-50. ■