

CASE REPORT

THE MONITORING OF HEMATOPOIETIC STEM CELL TRANSPLANT DONORS AND RECIPIENTS FROM ENDEMIC AREAS FOR MALARIA

Juliana INOUE(1), Clarisse Martins MACHADO(2), Giselle Fernandes Maciel de Castro LIMA(1), Maria de Jesus Costa NASCIMENTO(1), Vergílio Rensi COLTURATO(2) & Silvia Maria DI SANTI(1)

SUMMARY

Malaria is an unusual complication after hematopoietic stem cell transplantation in non-endemic countries. However, transplant candidates, recipients and donors living in endemic regions frequently report previous episodes of malaria. This fact could represent an important risk for immunosuppressed recipients that could develop severe malaria cases. We report a case of hematopoietic stem cell transplant (HSCT) in which the donor had a history of previous malaria, and close monitoring was performed before and after procedure by parasitological and molecular tests. The donor presented *Plasmodium vivax* in thick blood smears one month after transplant and was treated according to Brazilian Health Ministry guidelines. The polymerase chain reaction (PCR) was able to detect malaria infection in the donor one week earlier than thick blood film. Even without positive results, the recipient was pre-emptively treated with chloroquine in order to prevent the disease. We highlight the importance of monitoring recipients and donors in transplant procedures with the aim of reducing the risk of malaria transmission.

KEYWORDS: Hematopoietic stem cell transplantation; Malaria; Molecular diagnostic; Microscopy.

INTRODUCTION

Malaria is an acute infectious illness caused by *Plasmodium falciparum*, *P. vivax*, *P. malariae*, *P. ovale* and more recently *P. knowlesi* was considered the 5th human plasmodia¹⁹. Malaria cases due to *P. vivax*, the most prevalent species in Brazil, can present relapses in the absence of a new infection. It occurs because the hypnozoites, the dormant forms that persist in hepatocytes, can reactivate even after specific treatment and lead to a new malaria case. The dynamics of this mechanism is variable and the period of dormancy can range from one month to two years¹¹.

Malaria is an unusual complication after hematopoietic stem cell transplantation in non-endemic countries. However, transplant candidates, recipients and donors living in endemic regions frequently report previous episodes of malaria. In the setting of transplantation, transmission may occur by natural exposure to infected mosquitoes, or as an induced disease, through contaminated blood products or grafts^{15,18}. Careful investigation of past history of malaria is recommended due to the possibility of persistent disease, that can reach eight years for *P. falciparum*,⁹ three to five years for *P. vivax* and *P. ovale* and as long as 44 years for *P. malariae*¹⁴. In some non-endemic countries, donors who have lived in malaria areas are recommended

to be deferred from donation for three years or receive empiric treatment prior to donating^{12,17}. In endemic regions, a past history of malaria is not an exclusion criterion for donation. As post-transplant immunosuppression may facilitate parasite reactivation, screening before transplant as well as active surveillance with blood tests are strongly recommended. The detection of the parasite by thick blood smear allows species identification and quantification, nevertheless the sensitivity is low, is time consuming and not useful for blood donor screening¹⁰ or transplantation. However, nested PCR is highly sensitive, detecting as few as one parasite per microliter¹⁶, and therefore suitable for the detection of asymptomatic cases^{10,12}.

Symptomless cases with low parasitemia are due to development of immunity in adults, related to endemicity levels of the different areas^{1,6}. Some recent reports described symptomless infections, with 70% in Mato Grosso⁵ and 49.5% in Rondonia¹, both states in the Brazilian Amazon Region. The high prevalence of asymptomatic infections reported in Brazil is of great concern as the carriers are source of parasites for vectors and also can lead to induced malaria, as reported in a transfusion case, where the recipient died as a consequence of *P. malariae* infection⁸. The case report described here illustrates the complexity of malaria management after HSCT. Informed consent was obtained from patient's

(1) Malaria Research Center, Superintendence of Endemic Diseases Control, Health Secretariat of Sao Paulo State, Sao Paulo, SP, Brazil.

(2) Hematopoietic Stem Cell Transplant Program, Amaral Carvalho Foundation, Jau, SP, Brazil.

Correspondence to: Silvia M. Di Santi, Núcleo de Estudos em Malária, Superintendência de Controle de Endemias, Secretaria de Saúde do Estado de S. Paulo, Instituto de Medicina Tropical de São Paulo, Universidade de São Paulo, Av. Dr. Enéas de Carvalho Aguiar 470, sala 107, 05403 000 São Paulo, SP, Brasil. Phone/Fax: 55 11 3081 8039. E-mail: santi@usp.br

family, and the investigational protocol was approved by the Ethics Committee before the transplant.

CASE REPORT

The HSCT recipient and family, including his brother who was the only compatible donor available, lived in the city of Manaus located in the Amazon rain forest, an endemic region of malaria. While living in the endemic area, nine episodes of malaria have been reported by the donor during his lifetime, being the last one caused by *P. vivax* in January 2008. Due to the risk of malaria, blood monitoring was proposed to the donor and the HSCT recipient during the first three months after the HSCT. On July 3rd the donor, living at that time outside of an endemic area, presented with *P. vivax* malaria and was treated with chloroquine base in a total dose of 25 mg/kg over three days, and primaquine 0.50 mg/kg/day during seven days. The haemoscopic examination was negative on July 23rd 2008. Despite the complete treatment on September 2nd 2008, the donor presented symptoms related to malaria. On September 5th 2008 the donor was diagnosed with *P. vivax* relapse by thick blood film and was treated as previously.

In October 2008, the transplant candidate, a 6 year-old boy with acute lymphocytic leukemia (ALL) in 3rd remission was admitted at the Amaral Carvalho Foundation - HSCT Unit to receive an allogeneic peripheral blood stem cells (PBSC) transplant from his 15 year-old brother. The conditioning regimen consisted of cyclophosphamide plus total body irradiation (TBI) and HSCT was performed on October 16th 2008. Methotrexate and cyclosporine-A (CyA) was introduced for graft-versus-host disease (GVHD) prophylaxis. Neutrophil and platelet engraftment occurred on days 14 and seven after transplant, respectively. On day +10, the recipient presented febrile neutropenia and received 3rd generation cephalosporin for approximately 20 days. Blood samples from recipient and donor were collected weekly from October 14th 2008 to December 29th 2008 for blood smears and PCR tests. Thick blood films were performed and 2 mL of blood were lysed with 1% saponin before DNA extraction with Invisorb (Invitex, Berlin) and Brasilica (LGC Biotechnology, Brazil) kits. Nested PCR¹⁶ was accomplished with specific genus and species primers: rPLU5 and rPLU6 for genus and rVIV1/rVIV2, rMAL1/rMAL2 and rFAL1/rFAL2 for species (Invitrogen, Brazil). Fragments were resolved in 1% agarose gel with Blue Green Loading Dye (LGC Biotechnology, Brazil).

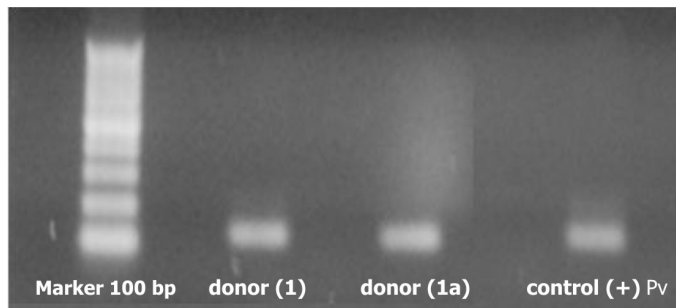


Fig. 1 - Nested PCR based on the amplification of the small-subunit rRNA gene sequence of *Plasmodium vivax* (120 bp). The PCR products were visualized in the 1% agarosis gel stained with Blue Green (LGC Biotec.). The DNA was acquired from two different extraction methodologies: (1) Invitex, (1a) Brasilica.

From October 14th 2008 to November 4th 2008 thick blood films were negative. On November 12th 2008 *P. vivax* was detected in hemoscopic exam of the donor, who was asymptomatic. Retrospective sample processing revealed that blood collected one week earlier contained malarial DNA (Fig 1). When malaria was diagnosed in the donor, the recipient was on day +26 and asymptomatic. Due to the possible risk of graft-transmitted malaria, the recipient received chloroquine base 25 mg/kg over three days. Primaquine was not given to the recipient because of the absence of the exoerythrocyte cycle in induced malaria cases. The donor was treated with chloroquine base 25 mg/kg over three days and primaquine 0.50 mg/kg/day for seven days, with clinical and parasitological cure. The HSCT recipient did not develop malaria and laboratorial monitoring from patient and donor remained negative during follow-up, until December 29th 2008 (Table 1). Unfortunately, the recipient died five months after HSCT due to ALL relapse.

DISCUSSION

Despite of the usual complications of transplants, tropical diseases as malaria, leishmaniasis, Chagas disease and others remain a challenge in endemic countries. Malaria transmission has been reported in kidney⁷, hematopoietic stem cell¹² and multiple tissue transplantation⁴.

The WHO gold standard method for malaria diagnosis is microscopy. It is considered inexpensive and field adapted. Despite being widely

Table 1
Polymerase chain reaction and thick blood film results according to time post-transplant

	Test	pre	◆	day +5 to +13	d+19	d+26	day +33 to +74
Donor	TBF	-		-	-	<i>Pv</i>	-
	PCR (<i>Pv</i> , <i>Pf</i> , <i>Pm</i>)	-		-	<i>Pv</i>	<i>Pv</i>	-
Recipient	TBF	-		-	-	-	-
	PCR (<i>Pv</i> , <i>Pf</i> , <i>Pm</i>)	-		-	-	-	-

pre = pre-transplant; HSCT = Hematopoietic Stem Cell Transplant; PCR = Polymerase Chain Reaction; *Pv* = *Plasmodium vivax*; ◆ = day of HSCT; *Pm* = *Plasmodium malariae*; TBF= Thick Blood Film; *Pf* = *Plasmodium falciparum*.

used, it requires specifically trained personnel and is not indicated for detection of low parasitemias. Rapid malaria diagnosis tests (RDTs) are unsuitable to detect submicroscopic parasitemia because of their relatively low sensitivity, mainly for non-*P. falciparum* malaria². However, asymptomatic cases of persistent malaria may occur and more sensitive techniques are necessary to reveal such unsuspected reservoirs of malaria.

This case highlights the importance of sensitive techniques in laboratory surveillance of malaria in patients and donors with epidemiological risk. Molecular detection methods are more sensitive and better adapted to automation allowing objective reading of results. In the present case, PCR could detect *Plasmodium* DNA in donor sample one week earlier than the blood film, confirming the diagnosis and allowing prophylactic intervention in the recipient. Although nested PCR increases the risk of contamination, the protocol chosen in the present report is well established, species-specific, able to detect one parasite/microliter and widely adopted in diagnosis and research of malaria¹⁶. The risk of contamination can be minimized when assays are carried out in well managed and controlled laboratories and with well trained and experienced staff, as was the case in this situation.

Pre-transplant screening of donors and recipients from endemic regions may not be enough to safely rule out persistent malaria. The diagnosis of *Plasmodium* infection in the donor during the follow up occurred just by chance, since he had no symptoms and also this kind of monitoring is not part of the routine approach in transplant centers in Brazil due to the general unavailability of molecular testing protocols locally. In this case, the monitoring was carried out by the Malaria Reference Center. Since the patient's family was planning to stay for three months in the city where the HSCT centre is located, we opted to monitor the donor who had a recent history of treated malaria. Although control tests were negative at pre-transplant screening, blood films and PCR turned positive during monitoring. In the follow up period, the donor presented with two episodes of malaria without the possibility of external reinfection, since he remained in a no transmission area. Relapses are due to reactivation of hypnozoites from the pre-erythrocytic cycle and can occur despite of complete treatment in a rate that varies from 8% to 24% in Brazil³. This mechanism can vary depending on *P. vivax* strain. As there are no sufficient data comparing primaquine treatment over seven and 14 days, the relapses presented by the HSCT donor could be a result of the short scheme used or failure in the drug absorption. This feature could lead to undetectable parasitemias and absence of symptoms in the beginning of the relapse. Since the HSCT centre city is not a malaria region in Brazil, the infection presented by donor was not a consequence of a new exposure to infected mosquitoes, but rather represent a case of persistent symptomless malaria. Unfortunately, when the diagnosis of malaria in the donor was made, the recipient had already received the graft and prompt treatment was therefore introduced due to the significant risk of malaria. Considering the possibility of malaria transmission reported here, the monitoring of donors and/or HSCT recipients living in endemic areas by both microscopy and molecular tests may represent a safer strategy to prevent graft-transmitted or induced malaria. In the absence of laboratory infrastructure, prophylactic treatment might be indicated to reduce the risk of infection¹⁷. However, in endemic countries the administration of antimalarials for donors and recipients could lead to unnecessary treatment, especially as some antimalarials present side effects. In our experience, none of six donors or recipients with previous

history of malaria developed the disease after follow-up, which varied from one to five years¹³. Even in non-endemic regions, the high frequency of traveling to malaria areas represents a risk of transmission, taking into account the possibility of symptomless cases in non-immune patients, as occurs in *P. malariae* infections⁸.

In this case, the detection of a relapse due to *P. vivax* in the donor revealed by thick blood film and confirmed using PCR allowed the prophylactic treatment of the recipient with a safe dosage of the antimalarial drug. Importantly, the follow-up of these cases by multidisciplinary teams enables better decisions, minimizing the risk for the recipient.

ETHICAL APPROVAL

All clinical and laboratorial procedures related to patients involved in this case were carried out according to Ethical Statements of both institutions. Experimental techniques were not applied.

RESUMO

Monitoramento de doadores e receptores provenientes de áreas endêmicas para malária em transplante de células-tronco hematopoiéticas

A malária é complicação incomum após o transplante de células-tronco hematopoiéticas em países endêmicos. No entanto, candidatos a transplantes, receptores e doadores que vivem em regiões endêmicas frequentemente relatam episódios anteriores de malária. Este fato pode representar um risco importante para receptores imunossuprimidos, que podem desenvolver casos de malária grave. Relatamos um caso de transplante de células-tronco hematopoiéticas (TCTH) em que o doador teve história de malária anterior e um monitoramento por meio de exames parasitológicos e moleculares foi realizado antes e após o procedimento. O doador apresentou *Plasmodium vivax* na gota espessa um mês após o transplante e foi tratado de acordo com as orientações do Ministério da Saúde brasileiro. A reação em cadeia da polimerase (PCR) foi capaz de detectar a infecção por malária no doador uma semana mais cedo do que a gota espessa. Mesmo sem resultados positivos, o receptor foi preventivamente tratado com cloroquina, a fim de prevenir as formas sanguíneas assexuadas. Destacamos a importância do monitoramento de receptores e doadores em procedimentos de transplante, com o objetivo de reduzir o risco de transmissão da malária.

ACKNOWLEDGEMENTS

This work was supported by: 1) Health Secretariat of Sao Paulo State and Tropical Medicine Institute of Sao Paulo, as part of a technical cooperation agreement; 2) Amaral Carvalho Foundation.

REFERENCES

1. Alves FP, Durlacher RR, Menezes MJ, Krieger H, Silva LH, Camargo EP. High prevalence of asymptomatic *Plasmodium vivax* and *Plasmodium falciparum* infections in native Amazonian populations. *Am J Trop Med Hyg*. 2002;66:641-8.
2. Belizário VY, Pasay CJ, Bersabe MJ, de Leon WU, Guerrero DM, Bugaoisan VM. Field evaluation of malaria rapid diagnostic tests for the diagnosis of *P. falciparum* and non-*P. falciparum* infections. *Southeast Asian J Trop Med Public Health*. 2005;36:552-61.

3. Boulos M, Amato Neto V, Dutra AP, Di Santi SM, Shiroma M. Análise da frequência de recaídas de malaria por *Plasmodium vivax* em região não endêmica (São Paulo, Brasil). *Rev Inst Med Trop Sao Paulo*. 1991;33:143-6.
4. Chiche L, Lesage A, Duhamel C, Salame E, Malet M, Samba D *et al*. Posttransplant malaria: first case of transmission of *Plasmodium falciparum* from a white multiorgan donor to four recipients. *Transplantation*. 2003;75:166-8.
5. de Andrade AL, Martelli CM, Oliveira RM, Arias JR, Zicker F, Pang L. High prevalence of asymptomatic malaria in gold mining areas in Brazil. *Clin Infect Dis*. 1995;20:475.
6. Gupta S, Day KP. A theoretical framework for the immunoepidemiology of *Plasmodium falciparum* malaria. *Parasite Immunol*. 1999;16:361-70.
7. Holzer BR, Glück Z, Zambelli D, Fey M. Transmission of malaria by renal transplantation. *Transplantation*. 1985;39:315-6.
8. Kirchgatter K, Nogueira SL, Padilha A, Curado I, Boulos M, Di Santi SM. Lethal malaria caused by *Plasmodium malariae* in an asplenic patient in Brazil. *BMJ*. 2005;331:576b-b6.
9. Kitchen A, Mijovic A, Hewitt P. Transfusion-transmitted malaria: current donor selection guidelines are not sufficient. *Vox Sang*. 2005;88:200-1.
10. Kitchen AD, Chiodini PL. Malaria and blood transfusion. *Vox Sang*. 2006;90:77-84.
11. Krotoski WA. The hypnozoite and malarial relapse. *Prog Clin Parasitol*. 1989;1:1-9.
12. Lefrère F, Besson C, Datry A, Chaibi P, Leblond V, Binet JL *et al*. Transmission of *Plasmodium falciparum* by allogeneic bone marrow transplantation. *Bone Marrow Transplant*. 1996;18:473-4.
13. Machado CM, Martins TC, Colturato I, Leite MS, Simone AJ, Souza MP *et al*. Epidemiology of neglected tropical diseases in transplant recipients. Review of the literature and experience of a Brazilian HSCT center. *Rev Inst Med trop Sao Paulo*. 2009;51:309-24.
14. Mungai M, Tegtmeier G, Chamberland M, Parise M. Transfusion-transmitted malaria in the United States from 1963 through 1999. *N Engl J Med*. 2001;344:1973-8.
15. O'Donnell J, Goldman JM, Wagner K, Ehinger G, Martin N, Leahy M *et al*. Donor-derived *Plasmodium vivax* infection following volunteer unrelated bone marrow transplantation. *Bone Marrow Transplant*. 1998;21:313-4.
16. Snounou G, Viriyakosol S, Zhu XP, Jarra W, Pinheiro L, do Rosario VE *et al*. High sensitivity of detection of human malaria parasites by the use of nested polymerase chain reaction. *Mol Biochem Parasitol*. 1993;61:315-20.
17. Tomblyn M, Chiller T, Einsele H, Gress R, Sepkowitz K, Storek J *et al*. Guidelines for preventing infectious complications among hematopoietic cell transplantation recipients: a global perspective. *Biol Blood Marrow Transplant*. 2009;15:1143-238.
18. Tran VB, Tran VB, Lin KH. Malaria infection after allogeneic bone marrow transplantation in a child with thalassemia. *Bone Marrow Transplant*. 1997;19:1259-60.
19. White NJ. *Plasmodium knowlesi*: the fifth human malaria parasite. *Clin Infect Dis*. 2008;46:165-71.

Received: 11 March 2010

Accepted: 15 July 2010