

C. Colosimo (✉) · F. E. Pontieri  
 I<sup>a</sup> Clinica Neurologica,  
 Dipartimento di Scienze Neurologiche,  
 Università La Sapienza,  
 v. dell'Università 30, I-00185 Rome, Italy  
 Tel.: 39 6 446 1982, Fax: 39 6 445 7705

Uta Meyding-Lamadé  
 Derk Krieger  
 Philipp Schnabel  
 Klaus Sartor  
 Falk Udo Sack  
 Peter Gass  
 Werner Hacke

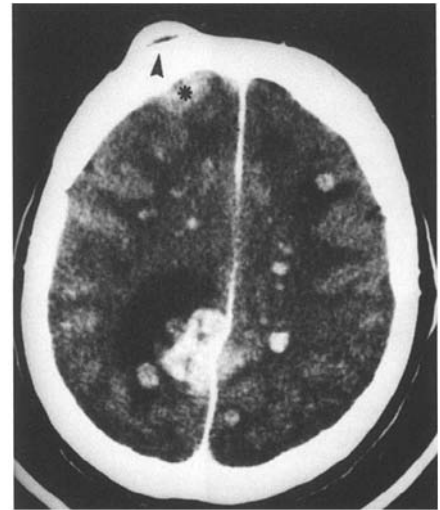
### Cerebral metastases of an allogenic renal cell carcinoma in a heart recipient without renal cell carcinoma

Received: 18 July 1995  
 Received in revised form:  
 28 November 1995  
 Accepted: 4 December 1995

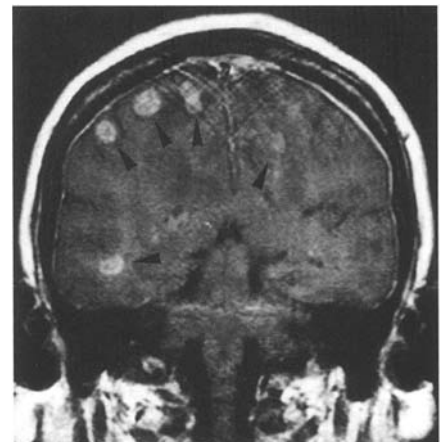
Sirs: Neurological complications after heart transplantation are mostly vascular in origin, such as prolonged pre- or intraoperative hypotension. Immunosuppressants are known to promote opportunistic infections and malignancies. We report on a 62-year-old woman with a several-week history of fatigue, decreasing alertness and a brachiofacial hemiparesis. She had undergone heart transplantation 12 months before and was put on a triple immunosuppressive treatment. CT and MRI revealed multiple, space-occupying lesions with an irregular ring enhancement at the corticomedullary junction.

The 62-year-old woman complained of being increasingly tired for weeks. In July 1993 she suffered a left-sided weakness, which developed gradually over several hours. In July 1992 a locally procured heart had been orthotopically transplanted in this patient. The transplantation was indicated because of long-standing severe dilating cardiomyopathy.

The recipient and the donor heart were explanted at the same time in order to shorten the time interval from explantation to implantation. After transplantation she was put on a triple immunosuppressive therapy including azathioprine, cyclosporine and steroids. She was known to have diabetes, which was well under control with a dietary regime. Neurological examination revealed a drowsy patient, who adequately followed simple commands. Visual field examination showed a homonymous hemianopia to the left, a left facial palsy and a left-sided hemiparesis. The left side of the face was hypaesthetic. Deep tendon reflexes were increased on the left, and the Babinski sign was present on the same side. The patient had a positive left-sided primitive grasp reflex and bilaterally positive crossed adductor reflexes. She had normal coordination and no signs of meningeal irritation. A soft lump, firmly attached to the underlying bone, was palpable on the right forehead. Cranial computed tomography (CT) and subsequent magnetic resonance imaging (MRI) with T2-weighted (TR 2400/20) and T1-weighted (TR 560/20) spin-echo images before and after application of gadolinium-DTPA (0.2 mmol/kg body weight) revealed multiple space-occupying lesions with an irregular ring enhancement, which were located predominantly at the corticomedullary junction of the cerebrum (Figs. 1, 2). Radiographs of the chest revealed postoperative changes following sternotomy, with a normal-sized heart and normal-appearing lungs. Abdominal CT and ultrasound were normal, revealing no primary or additional tumour. IgM-ELISA and IFT for toxoplasmosis were negative both in serum and CSF. Lumbar puncture showed 5 cells/mm<sup>3</sup>, elevated protein of 115 mg/dl (normal range 15–45), normal cytology, and negative ink staining for cryptococci. Biopsy of the right frontal lump revealed an allograft renal cell carcinoma metastasis, corresponding to cutaneous osteolytic metastases. Routine repeated right



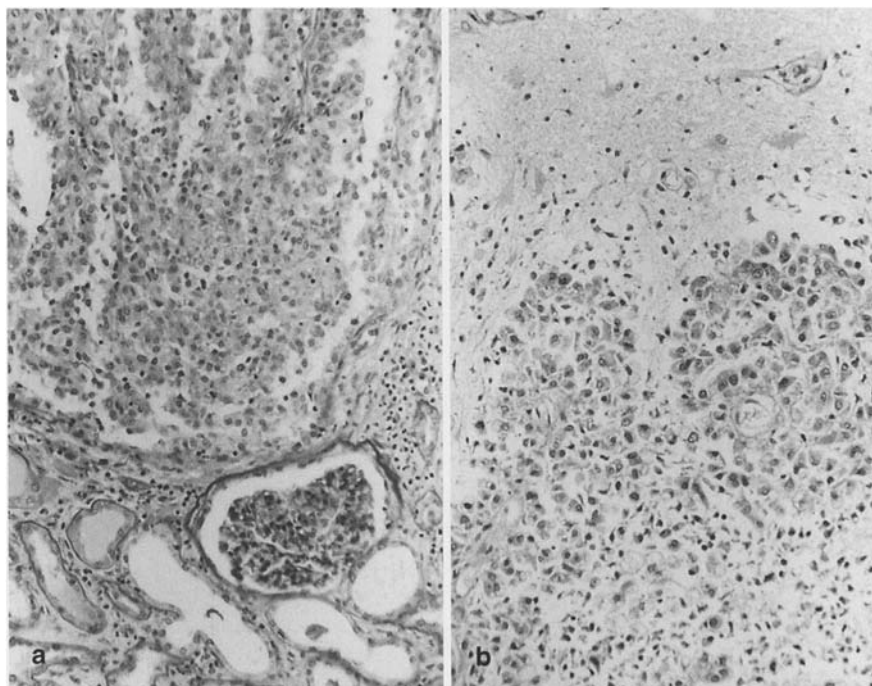
**Fig. 1** Cranial computed tomography (CT), slice thickness 5 mm, after administration of contrast media. There are multiple, space-occupying lesions with an irregular ring enhancement. One area in the right frontal lobe (*asterisk*) extended through the bone extracranially (*arrowhead*); biopsy revealed metastasis of renal cell carcinoma



**Fig. 2** Cranial magnetic resonance imaging of the same patient, 1.0 T Picker Vista Scanner. Coronal T1-weighted spin echo sequence, slice thickness 3 mm (SE 560/20), after application of gadolinium-DTPA (0.2 mmol/kg body weight). Bilaterally there are irregularly shaped, space-occupying lesions (some marked with an *arrowhead*) which are located at the corticomedullary junction and in the subcortical white matter with irregular ring enhancement, bilaterally in the parietal and basally in the right temporal lobe

ventricular heart biopsies were performed weekly during the 1st month,

**Fig. 3** **a** Histological examination of the donor's kidney (haematoxylin and eosin staining,  $\times 250$ ) revealed an undifferentiated renal cell carcinoma diffusely infiltrating the renal parenchyma. **b** Multiple metastases of the same tumour were disseminated in the brain. Haematoxylin and eosin staining,  $\times 250$



thereafter every 2 weeks for 5 months, every month for the following year and thereafter once a year. These biopsies were unremarkable with respect to renal cell carcinoma. Past medical history resolved the paradox: the heart donor, a patient with a trauma-related death had been in a good general state of health before, with an uneventful past medical or surgical history. However, this patient was accidentally found to have a renal cell carcinoma only detected at explantation of kidneys, liver and pancreas after the heart had been explanted (Fig. 3). Steroid therapy was continued in order to reduce increased intracranial pressure secondary to brain metastases. The patient recovered clinically for several months, but then deteriorated secondary to an increasing number of brain metastases, also increasing in size, and died. The autopsy confirmed the diagnosis of intracranial metastases of an allogenic renal cell carcinoma (Fig. 3).

The extracranial soft tissue lump in the right frontal region which originated intracranially and destroyed the bone was difficult to explain as representing infection or as lymphoma as these rarely extend or metastasize extracranially. Neuroradiological findings and clinical presentation suggested cranial metastases causing osteolytic destruction of the skull originating from the donor's renal cell carcinoma, which was discovered during implantation of the transplant organ. Intramyocardial vessels were free from blood of tumour cells. Therefore it seems unlikely that a few tumour cells were not eliminated during irrigation of

the heart. One may hypothesize that the heart already harboured micrometastases at the time of transplantation, although repeated routine biopsies of right ventricular trabeculae and of right atrial probes were free from tumour cells. In the immunosuppressed patient these were more likely to grow and lead to further metastases.

The spectrum of neurological complications (occurring in up to 70% of cases) in an immunosuppressed patient following cardiac transplantation includes ischaemic but rarely haemorrhagic vascular events, infections and neoplasms [4]. Cerebral ischaemic events are mostly due to perioperative hypotension or embolism and rarely petechial subarachnoid haemorrhage [1, 3, 5, 10]. Intracranial infectious complications [8] with multiple ring-enhancing lesions have been reduced to 5% using combination immunosuppressive regimens with cyclosporine, azathioprine and steroids [6]. The risk of infection is at its peak between 1 and 6 months after transplantation. Most often the clinical course is chronic, although *Listeria* and *Aspergillus* infections may evolve acutely within

days. *Aspergillus*, which accounts for nearly 25% of all infections, is mostly due to haematogenous spread from a pulmonary source which produces brain abscesses. CT reveals ring-enhancing or non-enhancing lesions that typically involve periaxial deep grey or white matter. Toxoplasmosis accounts for approximately 12% of intracranial infections occurring in most cases within the first 2 years following transplantation. While serological and CSF testing do not always help, ring-enhancing lesions (particularly if located in the basal ganglia) that improve on treatment within 2–4 weeks are diagnostic. *Cryptococcus* and *Listeria* account for 10% of infections each, presenting most often as chronic meningitis; rarely there may also be intracranial abscesses. Antigen determination is the most sensitive technique for diagnosis.

Lymphoproliferative disorders and solid tumours are the most common malignancies in the immunosuppressed patient, 2–10% of transplant patients developing tumours [2, 8, 9]. Intracranial metastases causing ring-enhancing lesions may be secondary to cancer of the lung, breast,

thyroid gland, kidney and skin as the most common primary site. Intracerebral lymphomas may occur multifocally, as may intracranial metastases. A frequent site of post-transplant lymphomas is the central nervous system (CNS). In 20–40% these lesions may be multicentric, often with invasion of the corpus callosum. On both CT and MRI lymphomas tend to enhance homogeneously after administration of contrast media. "Cystic, ring-enhancing" primary CNS lymphomas are a well-known entity in the AIDS.

Cancer in the potential donor is an exclusion criteria for organ transplantation. However, tumour transmissions from donor to recipient have been described following solid organ transplantation [7, 9]. Malignancy may be transferred in two settings as reported in two previous case reports: a non-traumatic intracerebral haemorrhage falsely attributed to a ruptured intracerebral vascular malformation [7], or a primary tumour in the donor that is unrelated to the donor's death and remains undetected [7]. The transferral of donor neoplasm by the transplanted organ is very rare, but has to be included in the differential diagnosis. In the past few years the incidence of death by natural causes (mostly intracranial haemorrhage) in donors has increased, whereas the number of trauma-related deaths of donors has decreased. A careful search for a potential primary tumour in a patient presenting with intracranial bleeding is crucial. It is even more difficult to detect a malignancy in a donor whose death is unrelated to this tumour. Organ procurement should include careful dissection of all intrathoracic and abdominal organs. Nevertheless all meticulous strategies may fail to identify small neoplasms. Therefore it is a future goal to convince the general population to become organ donors in order to increase the percentage of young donors, as young donors have a lower incidence of malignancies.

## References

1. Andrews BT (1991) The neurological complications of cardiac transplantation. *Surg Neurol* 35: 248–249
2. Chucrallah A, Crow MK, Lawrence ER, Rajagopalan S, Hudnall SD (1994) Multiple myeloma after cardiac transplantation: an unusual form of posttransplant lymphoproliferative disorders. *Hum Pathol* 25: 541–545
3. Emery RW, Cork RC, Levinson MM, Riley JE, Copeland J, McAleer MJ, Copeland JG (1986). The cardiac donor: a six-year experience. *Ann Thorac Surg* 41: 356–362
4. Hetzer R, Warnecke H, Schuler S, Suthoff U, Borst HG (1985) Heart transplantation – a two year experience. *Z Kardiol* 4: 51–58
5. Hosenpud JD, Novick RJ, Breen TJ, Daily OP (1994) The registry of the international society for heart and lung transplantation: eleventh official report – 1994. *J Heart Lung Transplant* 13: 561–570
6. Hotson JR, Enzmann DR (1988) Neurologic complications of cardiac transplantation. *Neurol Clin* 6: 349–365
7. Knoop C, Jacobovitz D, Antoine M, deFrancquen P, Yernault J-C, Estenne M (1994) Donor transmitted tumors in lung allograft recipients: report on two cases. *Transplantation* 57: 1679–1680
8. Montero CG, Martinez AJ (1986) Neuropathology of heart transplantation: 23 cases. *Neurology* 36: 1149–1154
9. Penn I (1982) Problems of cancer in organ transplantation. *Heart Transplant* 2: 71–77
10. Sila CA (1989) Spectrum of neurologic events following cardiac transplantation. *Stroke* 20: 1587–1589

U. Meyding-Lamadé (✉) · D. Krieger  
W. Hacke  
Department of Neurology, Kopfklinik,  
Im Neuenheimer Feld 400,  
D-69120 Heidelberg, Germany  
Tel.: 49-6221-568211,  
Fax: 49-6221-565348

K. Sartor  
Department of Neuroradiology,  
University of Heidelberg,  
Heidelberg, Germany

P. Schnabel  
Department of Pathology,  
University of Heidelberg,  
Heidelberg, Germany

F. U. Sack  
Department of Cardiac Surgery,  
University of Heidelberg,  
Heidelberg, Germany

P. Gass  
Department of Neuropathology,  
University of Heidelberg,  
Heidelberg, Germany

Ekrem Kutluay  
Zafer Çolakoglu  
Aysegül Dirlük  
Kamuran Kumral

## Brain SPECT in anterior opercular syndrome due to a unilateral lesion

Received: 23 August 1995  
Received in revised form:  
28 November 1995  
Accepted: 8 December 1995

Sirs: The operculum consists of the cortical mantle covering the insula. Perisylvian lesions involving the frontal, temporal and parietal operculum can lead to the anterior opercular syndrome (AOS) [7, 12]. AOS is a well-defined clinical entity with loss of voluntary control of the facial, pharyngeal, lingual and masticatory muscles. The reflex and automatic functions are, however, preserved. This is called "automatic voluntary dissociation" [1, 12] and has also been accepted as the cortical form of pseudobulbar palsy [11, 12]. It is almost always caused by bilateral vascular [7], infectious [7], developmental [5], tumoral [1] or degenerative [13] lesions in these regions. Occasionally opercular syndrome due to a unilateral lesion has also been reported [1, 10], but its special mechanism has not been explained.

We report a patient with AOS. Brain single photon emission computed tomography (SPECT) showed bilateral disturbance of regional cerebral blood flow (rCBF). Magnetic resonance imaging (MRI) failed to reveal this bilateral involvement.

A 73-year-old right-handed woman was admitted to hospital with sudden onset of weakness in the right hand and loss of speech. She was alert and fully oriented. Comprehension was normal. Her writing was distorted because of mild weakness of the right hand. There was a pseudoperipheral facial paralysis on the right side, bilateral loss of the