

CLINICAL CASE

Early-Onset *Candida glabrata* Interface Keratitis after Deep Anterior Lamellar Keratoplasty

Qihua Le*, Dan Wu†, Yimin Li*, Jian Ji†, Rongrong Cai†, and Jianjiang Xu*

ABSTRACT

Purpose. Fungal interface keratitis by *Candida* species can occur several weeks to several months after deep anterior lamellar keratoplasty (DALK). Here, we report a case of early-onset fungal interface keratitis by *Candida glabrata* after DALK.

Case Report. A 31-year-old Chinese man complained of decreased vision 4 days after an uneventful DALK for keratoconus. White to cream-colored interface deposits were identified under slit-lamp examination. The confocal scan disclosed clusters of hyperreflective granular deposits of 2 to 4 μm at the interface, without evidence of inflammation or hyphae-like structures. The graft was then removed, along with interface irrigation, and another graft was sutured. Finally, a penetrating keratoplasty was performed because the interface opacities recurred and deteriorated after graft replacement. Histopathological examination disclosed yeast-like structures at the retrocorneal side. The microbiologic results of both corneal scrapings taken from the recipient stromal bed and the removed half cornea button showed *C. glabrata*.

Conclusions. *Candida glabrata* interface keratitis can occur early after DALK, which can only be effectively treated with penetrating keratoplasty. Confocal microscopy is a promising tool to diagnose this rare complication. The importance of donor corneoscleral rim cultures should be emphasized during DALK.

(Optom Vis Sci 2015;92:e93–e96)

Key Words: *Candida glabrata*, deep anterior lamellar keratoplasty, interface keratitis

Deep anterior lamellar keratoplasty (DALK) is indicated in patients with corneal stromal disorders and an intact healthy endothelium, mainly keratoconus and scars. Benefits over penetrating keratoplasty include quicker visual rehabilitation, less demand on high quantity and quality of donor endothelium, and preservation of the host endothelium, thus minimizing the chances of immunological rejection and graft failure. Being an extraocular surgery, DALK also avoids the risks of intraoperative expulsive hemorrhage and intraocular infection as much as possible.

Descemet membrane perforation and the consequent double anterior chamber are the most common complications related with DALK.¹ Nevertheless, a rare complication after DALK is interface keratitis. The microbial infection between donor and host tissue has been reported to develop 5 days to 6 months postoperatively (PO).^{2–7} The most common causative microorganism was *Candida* species, which were identified in five cases.^{2–5}

Among the published cases, only one was caused by *Candida glabrata*, which occurred 2 months after surgery.² Here, we report a case of earlier-onset interface keratitis after DALK by *C. glabrata*. The clinical, confocal, histological, and microbiological characteristics are described.

CASE REPORT

A 31-year-old Chinese man underwent a penetrating keratoplasty in the right eye at a hospital in Beijing (2008) because of acute corneal hydrops in keratoconus. His left eye was then diagnosed as a subclinical keratoconus and he has been wearing a rigid gas-permeable contact lens since 2010. However, he complained of ineffective correction and ocular discomfort when wearing contact lens in the recent 6 months. Before the surgery, the uncorrected visual acuity (UCVA) of his right eye was 20/200 and he could be corrected to 20/25. The UCVA of the left eye was also 20/200, with no improvement with correction. The cornea of the left eye was clear under slit-lamp examination. No signs of scarring formation were visible. The average corneal power was 48.37 diopters (D). Corneal topography revealed that the steepest SimK was 50.98 D and the flattest SimK was 45.56 D. Central corneal thickness was 385 μm . The density of endothelial cells was 1393 cells/ mm^2 in the right eye and 2211 cells/ mm^2 in the left eye.

*MD, PhD

†MD

Department of Ophthalmology (QL, DW, YL, JX), Research Center (QL), Myopia Key Laboratory of Ministry of Health (QL, DW, JX), Department of Clinical Laboratory (JJ), and Department of Pathology (RC), Eye and ENT Hospital of Fudan University, Shanghai, China.

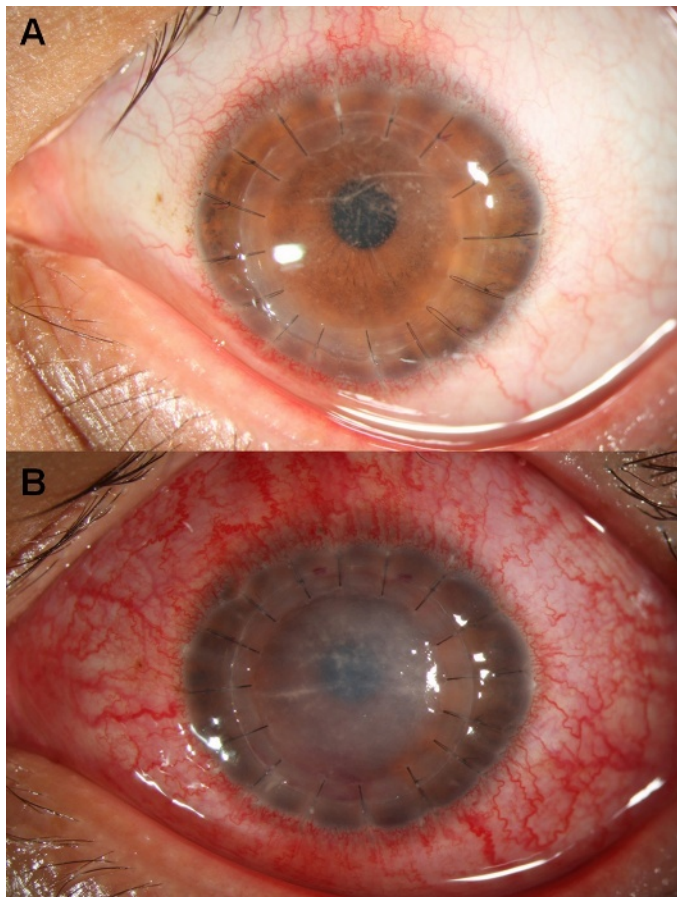


FIGURE 1.

(A) Slit-lamp photograph of the patient's left eye shows white cord-like deposits or small cream-colored plaques that were visible at the corneal interface on PO day 6 after DALK. (B) Diffuse whitish intrastromal opacities recurred and deteriorated on PO day 2 after interface irrigation and graft replacement.

He underwent a DALK in the left eye, with no complications during the surgery. The corneal graft was received from a certified US eye bank, and the seal on the tissue chamber remained intact before surgery. After transplantation, the medium was sent for culture. The patient was discharged on topical tobramycin 0.3% and

dexamethasone 0.1% four times a day. The graft was clear and UCVA was 20/100 at day 1 PO. However, at the first postoperative visit (6 days PO), he complained of blurred vision for 2 days, with UCVA decreasing to 20/400. White cord-like deposits or small cream-colored plaques were visible at the corneal interface under the slit-lamp examination, with little signs of inflammation (Fig. 1A). Anterior segment optical coherence tomography (AS-OCT) confirmed that the deposits were at the interface and spread unevenly (Fig. 2A). *In vivo* confocal microscopy (IVCM) revealed hyperreflective granular deposits, 2 to 4 μm in diameter, scattered at the interface and in distinct clusters (Fig. 2B). No evidence of inflammation or hyphae-like structures was found. The possibility of both hypovirulent bacteria infection and epithelial downgrowth was taken into consideration. Therefore, levofloxacin 0.5% was topically administered every 2 hours, along with fluorometholone 0.1% eye drops four times a day.

The alterations of therapeutic regimen seemed to lack a response because the interface lesions deteriorated on the next day. Therefore, the donor anterior lamellar graft was removed and divided into two parts, one for histopathological examination and the other for microbiological study. The corneal scrapings taken from the recipient stromal bed were also cultured. The interface was irrigated with cefuroxime 5% and fluconazole (0.8 g/L). The Descemet membrane was intact after irrigation, and one glycerol frozen-preserved graft was sutured. Levofloxacin 0.5% and fluconazole 0.5% eye drops were administered every 2 hours. Topical corticosteroids were discontinued.

However, diffuse whitish intrastromal opacities recurred at the interface on the second day after surgery (Fig. 1B), and it became more severe in the following two days. The findings of AS-OCT and IVCM were almost the same as those taken after the first surgery. Finally, a penetrating keratoplasty was performed because of a lack of response to the medical therapy and the clinical suspicion of fungal keratitis. Levofloxacin 0.5% and amphotericin B (1 mg/mL) eye drops were administered hourly for 3 days, along with the immunosuppressive agent, 0.1% tacrolimus ophthalmic solution, three times a day. Topical 0.5% voriconazole was added into the therapeutic regimen and administered hourly according to the findings of microbiological examination and antimicrobial susceptibility test.

The histopathological examination of the hematoxylin and eosin-stained sections showed clusters of round- to oval-shaped

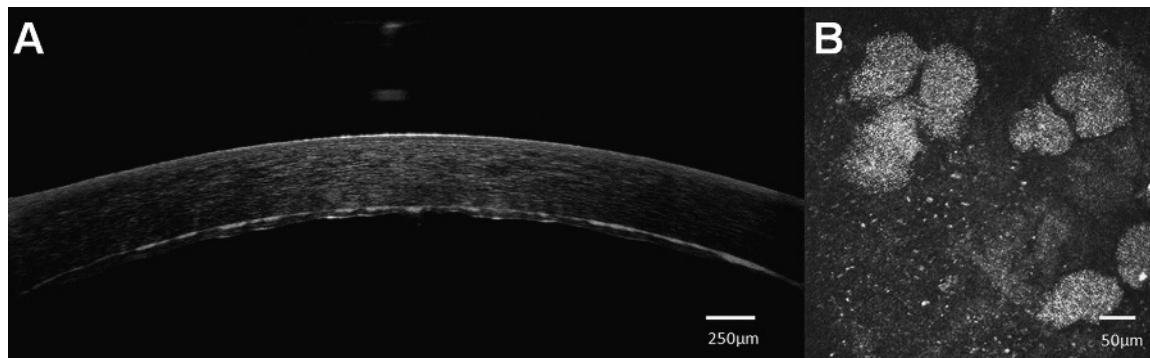


FIGURE 2.

(A) Image taken by AS-OCT confirmed that the deposits were at the interface and spread unevenly. (B) Small hyperreflective granular deposits measuring 2 to 4 μm in diameter were identified at the interface area on confocal scan, forming distinct clusters.

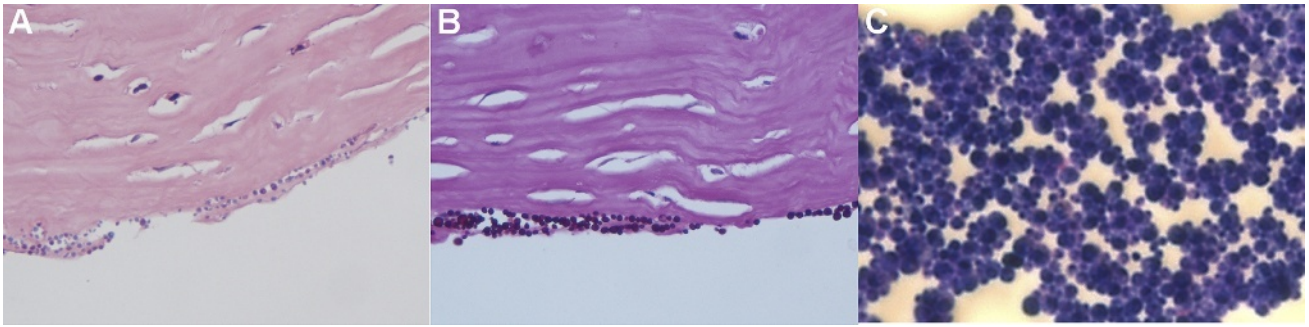


FIGURE 3.

Histopathological study showed that clusters of yeast-like structures were scattered at the retrocorneal side (A) (hematoxylin and eosin staining, 400 \times). The structures were also positive with periodic acid-Schiff staining (400 \times) (B) and Giemsa staining (1000 \times) (C).

structures measuring 2 to 4 μm in diameter that were scattering at the retrocorneal side (the interface region) (Fig. 3A). The structures were also positive with periodic acid-Schiff staining (Fig. 3B) and Giemsa staining (Fig. 3C). The yeast infection was verified by the cultures of both corneal scrapings taken from the recipient stromal bed and the removed half cornea button, which turn out to be *C. glabrata* (sensitive to amphotericin B, voriconazole, and caspofungin, and resistant to fluconazole and itraconazole).

The patient was discharged without signs of recurrence of the fungal interface keratitis with a UCVA of 20/200. The patient was followed up weekly. The graft remained clear at 5 months after surgery, with no evidence of recurrence. His UCVA and best-corrected visual acuity recovered to 20/80 and 20/40, respectively.

DISCUSSION

The pathogens causing interface keratitis after anterior lamellar keratoplasty (ALK) include *Candida albicans*,²⁻⁴ *C. glabrata*,² *Candida orthopsilosis*,⁵ *Mycobacterium chelonae*,⁶ and *Acanthamoeba*.⁷ According to previous reports, most fungal interface keratitis developed several weeks to several months after surgery. In the case reported by Kanavi et al.,² the first signs of interface keratitis by *C. glabrata* were noticed 2 months after DALK. However, in our case, the signs of infection caused by the same type of microorganism were manifest on day 4 after DALK, indicating a higher pathogenicity.

Candida glabrata has been considered a relatively nonpathogenic saprophyte of the normal flora of healthy subjects and certainly not readily associated with serious infection in humans for many years. However, with the increasing number of immunocompromised or debilitated hosts in recent years, the frequency of mucosal and systemic infections caused by *C. glabrata* has increased significantly.⁸ The risk factors for infection include prolonged hospitalization, repeated prior broad-spectrum antibiotic treatment along with immunosuppressive therapies, and more widespread use of indwelling medical devices.^{8,9} It has been shown that although *C. glabrata* only accounted for 3% of *Candida* isolates from sites other than blood in cancer patients, the mortality rate associated with *C. glabrata* is the highest compared with the infections caused by other non-*C. albicans* *Candida* species.⁹ Tappeiner et al.¹⁰ reported a case of exogenous *C. glabrata* endophthalmitis after penetrating keratoplasty in recipients of corneas from the same donor. Our finding also

confirmed that *C. glabrata* had a higher virulence than the other non-*C. albicans* *Candida* species.

The etiologies of interface keratitis after DALK include donor-to-host transmission,^{2,3} the recurrence of residual pathogen,^{6,7} and possible contamination of surgical instruments.⁵ It has been indicated that a donor cornea with a positive rim culture is a risk factor of donor-to-host transmission.¹¹ Potential predisposing donor risk factors for fungal contamination include cardiac disease as the cause of death, alcohol abuse, and prolonged death to preservation time of greater than 12 hours.¹¹ Unfortunately, although the culture of storage medium was performed and showed no growth, donor rim culture was not performed for this patient; hence, we could not disregard the possibility that there was a donor-to-host transmission.

In our case, efforts to treat interface keratitis failed after graft replacement, resulting in the need for a penetrating keratoplasty finally. Fontana et al.³ also tried to perform lamellar revision surgery in a patient with interface keratitis due to *C. albicans*. However, the keratitis worsened after revision surgery and the surgeon was forced to perform a full-thickness keratoplasty. It has been demonstrated by previous studies that the treatment of an interface keratitis after DALK should be a penetrating keratoplasty, although medical therapy or DALK might work in patients with interface keratitis after ALK. This is because interface keratitis after ALK is located up to the anterior or midstroma and an adequate clearance of infection can be expected with DALK. In post-DALK interface keratitis, the infection is already located in the deepest stroma, and interface irrigation and graft replacement would not be effective to completely remove the infectious tissue. Hence, a complete removal of the infectious tissue in the form of penetrating keratoplasty is required.

In this study, the confocal microscopic features of *C. glabrata* and its morphology under light microscope were almost the same as those reported by Kanavi et al.² and Roberts,¹² which were characterized with small granular deposits or blastoconidia measuring 2 to 4 μm in diameter, forming distinct clusters and having no evidence of pseudohyphae or hyphae formation. The size and the appearance of the hyperreflective structures at the interface region on confocal scan were almost parallel to those under light microscopy, indicating that IVCM might be a rapid and noninvasive way to diagnose this rare complication after DALK.

Two lessons should be learned from this case. One is that fungal interface keratitis can take place early after DALK, although most of

them were noticed after several weeks PO. Early-onset infectious interface keratitis after surgery indicates a higher pathogenicity, requiring a correct diagnosis and prompt treatment. *In vivo* confocal microscopy is a promising tool in the differential diagnosis. The other is that the culture of storage medium is inadequate. Performing fungal cultures on donor rim becomes even more essential with the growing popularity of DALK, and prophylactic antifungal treatment should be taken into consideration in cases of culture-positive fungal donor rims.

In conclusion, *C. glabrata* interface keratitis might occur early after DALK, and penetrating keratoplasty is a more effective way to treat this complication than interface irrigation and graft replacement. In cases where interface deposits are seen after lamellar corneal surgery, the possibility of *Candida* interface keratitis should be considered, and the necessary precautions should be taken before the infection spreads to the other segments of the eye.

ACKNOWLEDGMENTS

The first two authors contributed equally to this publication and should be considered co-first authors. This study was supported by National Natural Science Grants (81020108017, 81270014). None of the authors have any proprietary interests or conflicts of interest to disclose.

Received October 9, 2014; accepted December 23, 2014.

REFERENCES

- Noble BA, Agrawal A, Collins C, Saldana M, Brogden PR, Zuberbuhler B. Deep Anterior Lamellar Keratoplasty (DALK): visual outcome and complications for a heterogeneous group of corneal pathologies. *Cornea* 2007;26:59–64.
- Kanavi MR, Foroutan AR, Kamel MR, Afsar N, Javadi MA. *Candida* interface keratitis after deep anterior lamellar keratoplasty: clinical, microbiologic, histopathologic, and confocal microscopic reports. *Cornea* 2007;26:913–6.
- Fontana L, Parente G, Di Pede B, Tassinari G. *Candida albicans* interface infection after deep anterior lamellar keratoplasty. *Cornea* 2007;26:883–5.
- Bahadir AE, Bozkurt TK, Kutun SA, Yanyali CA, Acar S. *Candida* interface keratitis following deep anterior lamellar keratoplasty. *Int Ophthalmol* 2012;32:383–6.
- Wessel JM, Bachmann BO, Meiller R, Kruse FE. Fungal interface keratitis by *Candida orthopsilosis* following deep anterior lamellar keratoplasty. *BMJ Case Rep* 2013; doi: 10.1136/bcr-2012-008361 [Epub ahead of print].
- Murthy SI, Jain R, Swarup R, Sangwan VS. Recurrent non-tuberculous mycobacterial keratitis after deep anterior lamellar keratoplasty for keratoconus. *BMJ Case Rep* 2013; doi: 10.1136/bcr-2013-200641 [Epub ahead of print].
- Bi YL, Bock F, Zhou Q, Cursiefen C. Recurrent interface abscess secondary to *Acanthamoeba* keratitis treated by deep anterior lamellar keratoplasty. *Int J Ophthalmol* 2012;5:774–5.
- Rodrigues CF, Silva S, Henriques M. *Candida glabrata*: a review of its features and resistance. *Eur J Clin Microbiol Infect Dis* 2014;33:673–88.
- Silva S, Negri M, Henriques M, Oliveira R, Williams DW, Azeredo J. *Candida glabrata*, *Candida parapsilosis* and *Candida tropicalis*: biology, epidemiology, pathogenicity and antifungal resistance. *FEMS Microbiol Rev* 2012;36:288–305.
- Tappeiner C, Goldblum D, Zimmerli S, Fux C, Frueh BE. Donor-to-host transmission of *Candida glabrata* to both recipients of corneal transplants from the same donor. *Cornea* 2009;28:228–30.
- Kitzmann AS, Wagoner MD, Syed NA, Goins KM. Donor-related *Candida* keratitis after Descemet stripping automated endothelial keratoplasty. *Cornea* 2009;28:825–8.
- Roberts GD. Laboratory methods in basic mycology. In: Baron EJ, Finegold SM, eds. *Bailey & Scott's Diagnostic Microbiology*, 8th ed. St. Louis, MO: Mosby; 1990:741–59.

Jianjiang Xu

Department of Ophthalmology
Eye and ENT Hospital of Fudan University
Shanghai 200031
China
e-mail: jianjiangxu@126.com