

Case report

***Strongyloides* hyperinfection syndrome after intestinal transplantation**

G. Patel, A. Arvelakis, B.V. Sauter, G.E. Gondolessi, D. Caplivski, S. Huprikar. *Strongyloides* hyperinfection syndrome after intestinal transplantation.

Transpl Infect Dis 2008; **10**: 137–141. All rights reserved

Abstract: *Strongyloides stercoralis* is a helminth with the ability to autoinfect the human host and persist asymptomatically for several years. Immunosuppression can accelerate autoinfection and result in *Strongyloides* hyperinfection syndrome (SHS), which is associated with significant morbidity and mortality. Immunosuppressed solid organ transplant recipients, particularly in the setting of rejection, are at increased risk for reactivation of latent infections, such as *Strongyloides*. We describe a case of SHS in an intestinal transplant recipient; we hypothesize that she acquired the infection from the donor. We also review the current literature and address both prophylaxis and treatment of strongyloidiasis in the solid organ transplant patient.

G. Patel^{1,2}, A. Arvelakis³, B.V. Sauter^{2,4,5}, G.E. Gondolessi^{3,6}, D. Caplivski^{1,2}, S. Huprikar^{1,2}

¹Division of Infectious Diseases, ²Department of Medicine, ³Department of Surgery, Intestinal Rehabilitation and Transplantation Program, ⁴Division of Gastroenterology, Mount Sinai School of Medicine, New York, New York, USA, ⁵GastroZentrum Hirslanden, Zurich, Switzerland, ⁶Department of Nutrition, Rehabilitation, and Intestinal Transplant, Fundacion Favaloro, Buenos Aires, Argentina

Key words: *Strongyloides stercoralis*; intestinal transplant; *Strongyloides* hyperinfection syndrome

Correspondence to:

Shirish Huprikar, Division of Infectious Diseases, Mount Sinai School of Medicine, One Gustave L. Levy Place, New York, NY 10029 USA

Tel: + 212 241 6885

E-mail: shirish.huprikar@mssm.edu

Received 21 January 2007, revised 29 March, 2007, accepted for publication 17 April 2007

DOI: 10.1111/j.1399-3062.2007.00256.x

Transpl Infect Dis 2008; **10**: 137–141

Strongyloides stercoralis is endemic to Central and South America, Asia, Africa, parts of Europe, Puerto Rico, and the southeastern United States. Humans are the definitive host of this helminth and the pathogenesis of infection in the immunocompetent host has been described in detail (1). *S. stercoralis* has the rare ability to autoinfect the human host and establish latent infection that can persist for years without symptoms. Hyperinfection can occur when autoinfection accelerates in the setting of immunosuppression from underlying diseases or T-cell-depleting medications like corticosteroids and anti-thymocyte globulin (2). The *Strongyloides* hyperinfection syndrome (SHS) has been associated with mortality rates as high as 87% in the immunocompromised host (3).

Transplant recipients are at risk for reactivation of latent infections including *S. stercoralis*. In the solid organ transplant literature, most reported cases of SHS or disseminated strongyloidiasis are consequences of intensified

immunosuppression in the setting of recent allograft rejection. Although most cases are a result of latent infection in the recipient, there are a few case reports of strongyloidiasis acquired from the donor (4–6). We describe a case of SHS in an intestinal transplant recipient who had no clinical evidence of occult parasitic infection before transplantation.

Case report

A previously healthy 62-year-old Italian-American woman from New York City underwent elective knee replacement surgery in August 2004. Her postoperative course was complicated by heparin-induced thrombocytopenia and superior mesenteric artery thrombosis that resulted in an emergent total enterectomy. In December 2004, she

underwent intestinal transplantation. Post-transplantation immunosuppression consisted of induction therapy with basiliximab and maintenance therapy with tacrolimus, mycophenolate mofetil, and corticosteroids. Her early post operative course was complicated by carbapenem-resistant *Klebsiella pneumoniae* peritonitis that was treated and cured with polymyxin B and tigecycline in addition to a reduction in immunosuppression.

In January 2005, biopsies of the allograft revealed severe acute exfoliative rejection. The patient was treated with high-dose methylprednisolone, anti-thymocyte globulin, intravenous immunoglobulin, rituximab, and plasmapheresis. Subsequent biopsies revealed no further rejection. The patient was discharged in March 2005 and several outpatient biopsies revealed non-specific inflammation. She underwent reversal of her enterostomy in August 2005. Three weeks later, the patient was tolerating food and was discharged home on prednisone 7.5 mg daily, mycophenolate mofetil 250 mg twice a day, tacrolimus 5 mg twice a day, valganciclovir 450 mg daily, and warfarin.

Ten days after discharge, the patient developed nausea, vomiting, constipation, and diffuse abdominal discomfort. These symptoms were accompanied by low-grade fevers, headaches, and photophobia without associated neck stiffness or pain. Endoscopy was performed to exclude allograft rejection or viral infection. Her temperature continued to escalate and she became increasingly tachypneic. Chest radiographs and chest CTscan revealed rapid development of bilateral interstitial infiltrates (Figs. 1 and 2). The patient was intubated and transferred to the intensive care unit.

Peripheral blood cultures from the day of admission grew vancomycin-sensitive *Enterococcus faecium* and carbapenem-susceptible ESBL-producing *K. pneumoniae*. The patient was treated with vancomycin and imipenem. Biopsies of both the small bowel and the colon revealed diffuse infestation with *S. stercoralis* (Fig. 3). Microscopic evaluation of bronchoalveolar lavage specimens also demonstrated larvae confirming SHS (Fig. 4). Treatment was initiated with both ivermectin (200 µg/kg daily) and thiabendazole (25 mg/kg twice a day) by a nasogastric tube as well as daily ivermectin retention enemas (15 mg suspended in Oraplus®). Endoscopy performed 10 days into therapy demonstrated no larvae. Concurrent examination of sputum and stool also failed to demonstrate persistent larvae.

Lumbar puncture was initially deferred due to warfarin-associated coagulopathy. When performed 4 weeks into hospitalization for lethargy, the cerebrospinal fluid revealed a neutrophilic pleocytosis consistent with bacterial meningitis. Although cultures from the initial lumbar puncture were negative, the patient had a concomitant carbapenem-resistant *Pseudomonas aeruginosa* bacteremia

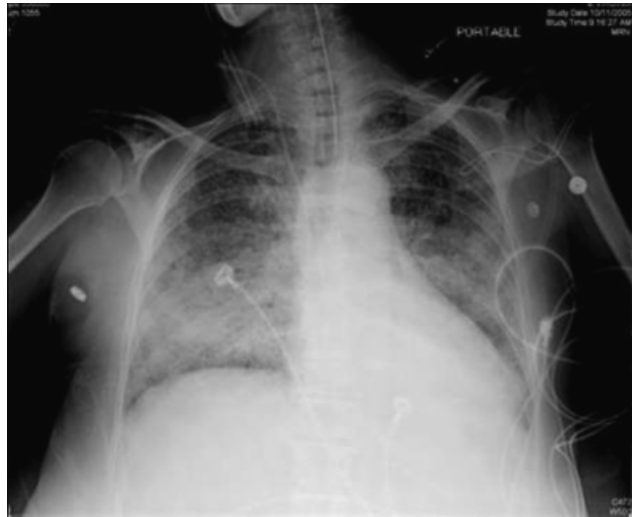


Fig. 1. Chest radiograph with rapid development of bilateral interstitial infiltrates.

and it was assumed that this organism was also the etiology of her meningitis. She was treated with intravenous ceftazidime and ciprofloxacin. Repeat lumbar puncture performed 1 week later showed significant improvement in the pleocytosis, but Gram stain and culture now revealed vancomycin-susceptible *E. faecium* meningitis. Linezolid was added in order to treat the presumed polymicrobial meningitis because the patient had previously received an extended course of vancomycin for *E. faecium* bacteremia.

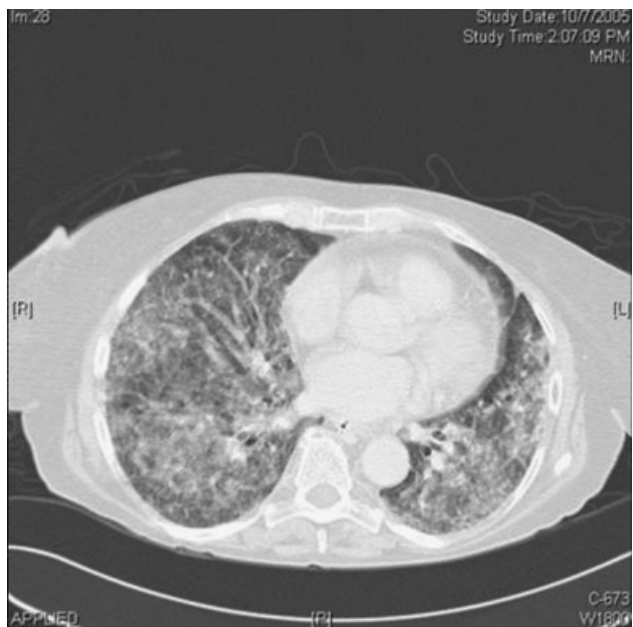

Fig. 2. Computed tomography scan confirming the acute development of bilateral interstitial infiltrates.

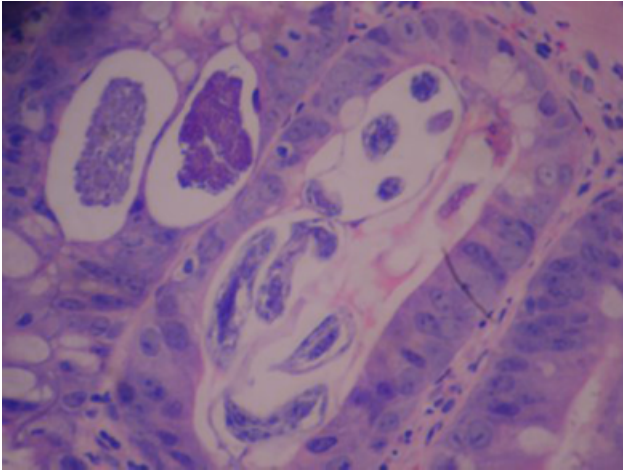


Fig. 3. Both larval forms and thin-walled ova were visible in the crypts of the transplanted bowel.

Cerebrospinal fluid collected from both lumbar punctures did not reveal any larvae.

Following a prolonged and complicated intensive care unit stay, the patient eventually recovered and was transferred to the transplantation unit. Her hospital course was further complicated by invasive pulmonary aspergillosis and disseminated cytomegalovirus infection. In February 2006, she developed *Acinetobacter* septicemia and died. The patient's family declined autopsy.

Review of hospital records from before transplantation demonstrated no history of unexplained eosinophilia, gastrointestinal symptoms, or sick contacts. The patient denied any personal history of traveling to areas endemic for *S. stercoralis* in either the United States or abroad to suggest reactivation of previously acquired latent infection. She had no pets. Previous biopsies of the graft were reviewed

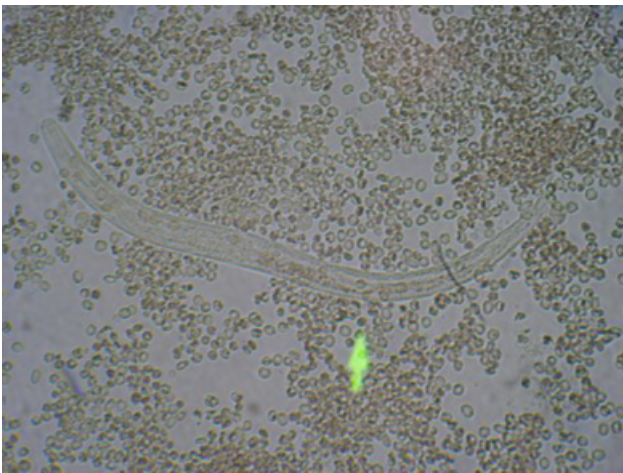


Fig. 4. Motile rhabditiform larvae were demonstrated in the bronchoalveolar lavage specimen.

retrospectively and did not demonstrate *S. stercoralis*. The donor was a 39-year-old Honduran man who was living in Ft. Lauderdale, Florida, and was pronounced brain-dead after a motor vehicle accident.

Discussion

To our knowledge, this is the first reported case of SHS in an intestinal transplant recipient. We believe that the donor graft was possibly the source of *Strongyloides* in our patient.

SHS in renal allograft recipients has been extensively reviewed (7, 8). Unlike our case, the majority of reported cases were apparent within 3 months of transplantation (8). Cases in transplant recipients often occur in the context of increased doses of corticosteroids and intensified immunosuppression used to treat allograft rejection. The diagnosis of strongyloidiasis is often serendipitous. Nonspecific signs and symptoms and a lack of suspicion result in frequent delays in diagnosis and treatment (7). In our patient, the diagnosis was made on the basis of a biopsy that was performed to evaluate for rejection and viral infection.

Since the use of cyclosporine became standard in renal transplant protocols, there is a paucity of reported cases of symptomatic strongyloidiasis in transplant recipients (6). Experimental (9) and observational anecdotes suggest that cyclosporine has anthelmintic properties. All reported cases of *Strongyloides* infection in the solid organ transplant literature since 1990 have been in patients receiving cyclosporine-sparing regimens (5, 6, 10–13). The risk of developing donor-acquired strongyloidiasis may be greater in intestinal transplant recipients, as the intestinal tract is the site of latent infection. Cyclosporine is not used routinely in intestinal transplantation owing to high rejection rates (14–17). Tacrolimus, the primary immunosuppressant used in intestinal transplantation, is not associated with anthelmintic properties (17).

Most cases of strongyloidiasis in transplant recipients are due to reactivation of latent infection in the recipient. Most infected transplant recipients had evidence of infection before transplantation including unexplained eosinophilia, chronic gastrointestinal symptoms, documented *Strongyloides* infection, or a history of concomitant parasitic infection (7). Our patient had no evidence of persistent eosinophilia or other signs or symptoms of latent infection.

The donor has been reported as a rare source of strongyloidiasis in transplant recipients. Hoy et al. (4) reported the development of disseminated strongyloidiasis in both recipients of the renal allografts from a single donor. More

recently, Ben-Youssef et al. (5) described strongyloidiasis in a pancreas allograft recipient with no exposure to an endemic area. Donor infection was confirmed retrospectively by an enzyme-linked immunosorbent assay. Other organ recipients from the same donor are reported to be asymptomatic. It is not clear whether asymptomatic recipients received preemptive therapy, harbored asymptomatic infections, received cyclosporine, or were simply not infected.

We speculate that latent infection in the donor was transmitted to our patient who lacked clinical or epidemiologic evidence of latent infection. The donor, on the other hand, had lived in areas endemic for *Strongyloides*, having been born and raised in Honduras and residing in Florida at the time of his death. Because of the late presentation of SHS after transplantation in our case, donor or recipient serum was not available to confirm serologic status before transplantation. To date, *Strongyloides* infection has not been reported in the recipients of other organs (kidneys, pancreas, liver, and heart) from this donor. We hypothesize that the other recipients have been spared from disease because the immunocompetent donor had latent infection limited to the intestinal tract.

We acknowledge that if this was truly a donor-derived infection, our patient should have demonstrated evidence of parasitic infestation early in her post-transplantation course, especially in the setting of acute allograft rejection. We have no explanation for the late onset of SHS in our patient. Although it is a remote possibility that the parasite was acquired in the healthcare setting, it is highly unlikely as our patient was maintained on contact isolation for the duration of her prolonged hospitalization, including before transplantation.

The ideal treatment of SHS is not established. Single-dose ivermectin is the treatment of choice in immunocompetent patients with intestinal strongyloidiasis (1). Treatment duration for SHS using thiabendazole monotherapy ranges from 5 to 14 days (8, 10). More aggressive regimens for SHS use thiabendazole and ivermectin for variable durations (11). Some patients may require multiple courses of therapy because of persistent active infection. It has been suggested that survivors of SHS should be treated monthly for at least 6 months (7, 8). There is compelling evidence that reactivation can occur in transplant recipients even after documented treatment (8). These patients may benefit from indefinite therapy but studies to support this practice are lacking.

A challenge in the treatment of SHS is that patients often suffer from paralytic ileus or intestinal obstruction, preventing both administration and absorption of oral agents. Because no accepted parenteral therapy exists, alternative treatment modalities such as subcutaneous (3, 18, 19) and rectal formulations have been used. Parenteral ivermectin

is used routinely in veterinary medicine. Two recent cases in the literature describe the successful use of subcutaneous veterinary-grade ivermectin in the treatment of patients with SHS suffering from paralytic ileus (18, 19). After 3 doses of subcutaneous veterinary ivermectin (200 µg/kg), the patients achieved higher serum drug levels than with enteral drug administration alone. These higher serum levels correlated with a substantial decrease in detectable parasite burden. Diarrhea in one patient precluded the use of rectal formulations of ivermectin or thiabendazole.

Administration of retention enemas was first described with thiabendazole (20). Peak plasma concentrations of the medication were achieved within 4 h of rectal administration and were sustained longer than with the standard oral formulation. Tarr et al. (11) reported a case of SHS in a cadaveric renal transplant recipient who was refractory to enteral albendazole and ivermectin owing to paralytic ileus. This patient was successfully treated with combination enteral therapy and daily ivermectin retention enemas (11). For our patient, we substituted albendazole with thiabendazole and achieved similar results.

Our case highlights the importance of developing rational strategies to prevent *Strongyloides* infections in transplant recipients. Donors and recipients who have resided in endemic areas should be screened for *Strongyloides* infection before transplantation (21). Donors and recipients with a history of other helminthic infections, unexplained eosinophilia, or unexplained gastrointestinal complaints should also be screened (2, 7). Serology may be less sensitive in relatively immunocompromised patients, such as potential transplant recipients (1, 2). Diagnostic yield may be greater with examination of stool for ova and parasites in conjunction with serology. Previous recommendations advocate that transplant candidates with evidence of *Strongyloides* infection be treated before transplantation with thiabendazole 25 mg/kg twice daily for 3 days with documented negative stool ova and parasite exams before transplantation (7). We favor ivermectin therapy for seropositive individuals and believe that transplantation should be delayed until ova and parasites are no longer detected in the stool. We agree with recommendations that family members and pets should also be screened and treated as potential sources of re-infection post transplantation (10).

Pre-transplant screening of the deceased donor before organ procurement is not practical. Targeted serologic screening for *Strongyloides* in donors from endemic areas may provide useful information for the physicians caring for the recipients of organs from an untreated cadaveric donor with latent *Strongyloides*. Although formal studies are lacking, pre-emptive treatment in these recipients may prevent disease.

We report the first case of SHS in an intestinal transplant recipient who may have acquired the infection from the donor. Our case highlights the importance of considering this disease and implementing preventive strategies in the recipients of transplants from endemic areas.

References

- Mahmoud AAF. Strongyloidiasis. *Clin Infect Dis* 1996; 23: 949–953.
- Kaiser PB, Nutman TB. *Strongyloides stercoralis* in immunocompromised populations. *Clin Micro Rev* 2004; 17: 208–217.
- Pacanowski J, Santos MD, Roux A, et al. Subcutaneous ivermectin as a safe salvage therapy in *Strongyloides stercoralis* hyperinfection syndrome: a case report. *Am J Trop Med Hyg* 2005; 73: 122–124.
- Hoy WE, Roberts NJ, Bryson MF, et al. Transmission of strongyloidiasis by kidney transplant? Disseminated strongyloidiasis in both recipients of kidney allografts from a single cadaver donor. *JAMA* 1981; 246: 1937–1939.
- Ben-Youssef R, Baron P, Edson F, Raghavan R, Okechukwu O. *Strongyloides stercoralis* infection from pancreas allograft: case report. *Transplantation* 2005; 80: 997–998.
- Palau LA, Pankey GA. Strongyloides hyperinfection in a renal transplant recipient receiving cyclosporine: possible *Strongyloides stercoralis* transmission by kidney transplant. *Am J Trop Med Hyg* 1997; 57: 413–415.
- Morgan JS, Schaffner W, Stone WJ. Opportunistic strongyloidiasis in renal transplant recipients. *Transplantation* 1986; 42: 518–523.
- Devault GA, King JW, Rohr MS, Landreneau MD, Brown ST, McDonald JC. Opportunistic infections with *Strongyloides stercoralis* in renal transplantation. *Rev Infect Dis* 1990; 12: 653–671.
- Schad GA. Cyclosporine may eliminate the threat of overwhelming strongyloidiasis in immunosuppressed patients. *J Infect Dis* 1986; 153: 178.
- Schaeffer MW, Buell JF, Gupta M, Conway GD, Akhter SA, Wagoner LE. *Strongyloides* hyperinfection syndrome after heart transplantation: case report and review of the literature. *J Heart Lung Transplant* 2004; 23: 905–911.
- Tarr PE, Miele PS, Peregoy KS, Smith MA, Neva FA, Lucey DR. Case report: rectal administration of ivermectin to a patient with *Strongyloides* hyperinfection syndrome. *Am J Trop Med Hyg* 2003; 68: 454–455.
- Soman R, Vaideeswar P, Shah H, Almeida AF. A 34 year old renal transplant recipient with high-grade fever and progressive shortness of breath. *J Postgrad Med* 2002; 48: 191–196.
- El Masry HZ, O'Donnell J. Fatal *Strongyloides* hyperinfection in heart transplantation. *J Heart Lung Transplant* 2005; 24: 1980–1983.
- Brousse N, Goulet O. Small bowel transplantation. *Br Med J* 1996; 312: 261–262.
- Tzakis AG, Todo S, Reyes J, et al. Intestinal transplantation in children under FK506 immunosuppression. *J Pediatr Surg* 1993; 28: 1040–1043.
- Grant D, Abu-Elmagd A, Reyes J, et al. 2003 Report of the Intestine Transplant Registry: a new era has dawned. *Ann Surg* 2005; 241: 607–613.
- Nolan TJ, Schad GA. Tacrolimus allows autoinfective development of the parasitic nematode *Strongyloides stercoralis*. *Transplantation* 1996; 62: 1038.
- Turner SA, Maclean JD, Fleckenstein L, Greenaway C. Parenteral administration of ivermectin in a patient with disseminated strongyloidiasis. *Am J Trop Med Hyg* 2005; 73: 911–914.
- Marty FM, Lowry CM, Rodriguez M, et al. Treatment of human disseminated strongyloidiasis with a parenteral veterinary formulation of ivermectin. *Clin Infect Dis* 2005; 41: e5–e8.
- Boken DJ, Leoni PA, Preheim LC. Treatment of *Strongyloides stercoralis* hyperinfection syndrome with thiabendazole administration per rectum. *Clin Infect Dis* 1993; 16: 123–126.
- Screening of donor and recipient prior to solid organ transplantation. *Am J Transplant* 2004; 4 (Suppl 10): 10–20.