

## Intentional Use of *Schistosoma mansoni*-Infected Grafts in Living Donor Liver Transplantation

Received February 15, 2012; accepted March 8, 2012.

### TO THE EDITORS:

We read with great interest the article by Vincenzi et al.,<sup>1</sup> who reported *Schistosoma mansoni*-infected liver grafts that were transplanted incidentally in the context of pediatric living donor liver transplantation (LDLT). Extended criteria have been used for donors in order to expand the pool of available grafts.<sup>2</sup> In LDLT, the actual policy does not differ, and expanded criteria for living donors have allowed conditions such as steatosis, advanced age, and dual grafts.<sup>3</sup> The authors highlighted the impact of liver transplants infected by *S. mansoni* on the donors and the recipients. Their outcomes were good, with no harm to either the donors or the recipients.

In 2009, we performed 148 liver transplants at the Clinical Hospital of the University of Sao Paulo School of Medicine. Eight of these transplants were LDLT procedures in adults, and 1 donor was known to have an *S. mansoni*-infected liver. Because of the suspicion of moderate steatosis, this healthy, 36-year-old man underwent liver biopsy, which revealed epithelioid granulomas with *Schistosoma* eggs and 30% macrovesicular steatosis (Fig. 1). The donor lost 5 kg, and ultrasound imaging no longer showed steatosis. Our experience with *S. mansoni*-infected patients (in most of whom liver function was preserved) and a few reports in the literature of incidentally found schistosomiasis in transplant patients with good outcomes<sup>4,5</sup> led us to proceed with LDLT despite the liver biopsy findings. We used the left lobe with the middle hepatic vein. The donor surgery was uneventful. The recipient was a 27-year-old man with primary sclerosing cholangitis and a Model for End-Stage Liver Disease score of 14. His liver enzyme levels were normally decreasing, but he started to have signs of infection on postoperative day 4. Computed tomography showed wall thickening of the colon, intestinal pneumatosis, and portal pylephlebitis. He subsequently died of sepsis on postoperative day 14. The donor recovered well, was active in sports, and had no complaints after 2 years of follow-up. In the same year, we also per-

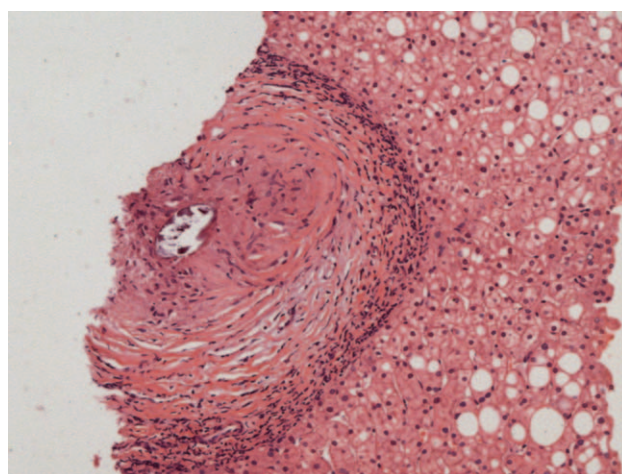


Figure 1. Liver biopsy sample showing an epithelioid granuloma with a *Schistosoma* egg and 30% macrovesicular steatosis.

formed LDLT with a graft from a donor with *Schistosoma* eggs in his feces. This 31-year-old man was treated with praziquantel before surgery. He once underwent liver biopsy, which did not show the presence of granulomas. The surgery was right hepatectomy (including the right hepatic vein). The recipient, a 57-year-old man with hepatitis B cirrhosis and hepatocarcinoma, had a good outcome. The donor and the recipient had no complications, and they were doing well after 2 years of follow-up. Both cases reported were approved by the transplant committee.

In certain tropical countries such as Brazil, schistosomiasis is endemic, and the number of infected individuals is quite high: millions of people are affected.<sup>6</sup> Thus, the chance of incidentally finding an infected graft is not low. Perhaps more grafts of this kind have been used and missed simply because people are not looking for them. However, we do not recommend that all donors be tracked because such a project would not be cost-effective and is unnecessary on account of the good outcomes of these organs. Moreover, after the acute phase, *S. mansoni* remains in the intestine,

Address reprint requests to Wellington Andraus, M.D., Ph.D., Rua Aracaju 42, Ap 41, Sao Paulo, Brazil 01240030. Telephone: 55 11 3061-8319; FAX: 55 11 2661 3323 or 55 11 2661 9008; E-mail: wellington@usp.br

DOI 10.1002/lt.23436

View this article online at wileyonlinelibrary.com.

LIVER TRANSPLANTATION. DOI 10.1002/lt. Published on behalf of the American Association for the Study of Liver Diseases

and inside the liver, we can identify only necrotic eggs producing granulomatous inflammation. Therefore, the disease is unlikely to be transmitted by liver transplantation.

In all cases reported in the literature, schistosomiasis was not identified until after transplantation.<sup>1,4,5</sup> The cases that we describe here are the first in which a donor organ was used with full knowledge of the diagnosis. As mentioned by Vincenzi et al.,<sup>1</sup> during the early stage of the disease, patients are asymptomatic, and liver function is preserved. We agree with the authors that the presence of *Schistosoma* eggs in the liver is not a contraindication for donation itself. Although some doctors have refused to use grafts infected by *S. mansoni*,<sup>7,8</sup> our experience with liver resection in these patients allowed us to perform the first cases. In summary, we believe that it is reasonable to use *S. mansoni*-infected grafts in cadaveric liver transplantation or LDLT, but a long-term evaluation with a larger number of cases is still necessary.

Wellington Andraus, M.D., Ph.D.

Vicenzo Pugliese, M.D., Ph.D.

Rafael Pecora, M.D.

Luiz Augusto C. D'Albuquerque, M.D., Ph.D.

University of Sao Paulo School of Medicine  
Sao Paulo, Brazil

## REFERENCES

1. Vincenzi R, Neto JS, Fonseca EA, Pugliese V, Leite KR, Benavides MR, et al. *Schistosoma mansoni* infection in the liver graft: the impact on donor and recipient outcomes after transplantation. *Liver Transpl* 2011;17:1299-1303.
2. Durand F, Renz JF, Alkofer B, Burra P, Clavien PA, Porte RJ, et al. Report of the Paris consensus meeting on expanded criteria donors in liver transplantation. *Liver Transpl* 2008;14:1694-1707.
3. Moon D, Lee S, Hwang S, Kim K, Ahn C, Park K, et al. Resolution of severe graft steatosis following dual-graft living donor liver transplantation. *Liver Transpl* 2006;12:1156-1160.
4. Pungpapong S, Krishna M, Abraham SC, Keaveny AP, Dickson RC, Nakhleh RE. Clinicopathologic findings and outcomes of liver transplantation using grafts from donors with unrecognized and unusual diseases. *Liver Transpl* 2006;12:310-315.
5. Pannegoon V, Masini JP, Paye F, Chazouillères O, Girard PM. *Schistosoma mansoni* infection and liver graft. *Transplantation* 2005;80:287.
6. Katz N, Peixoto SV. Critical analysis of the estimated number of *Schistosomiasis mansoni* carriers in Brazil [in Portuguese]. *Rev Soc Bras Med Trop* 2000;33:303-308.
7. Nadalin S, Malagó M, Valentin-Gamazo C, Testa G, Baba HA, Liu C, et al. Preoperative donor liver biopsy for adult living donor liver transplantation: risks and benefits. *Liver Transpl* 2005;11:980-986.
8. Tran TT, Changsri C, Shackleton CR, Poordad FF, Nissen NN, Colquhoun S, et al. Living donor liver transplantation: histological abnormalities found on liver biopsies of apparently healthy potential donors. *J Gastroenterol Hepatol* 2006;21:381-383.