

of 5 mg/kg twice per day and i.v. immunoglobulin (5 g/day for 3 days) was started. Blood culture was negative for any pathogens. Serologic tests for autoimmune diseases and fungal antigen tests as well as viruses, including echovirus, coxsackie virus, and human immunodeficiency virus (HIV), were all negative. Serologic tests for toxoplasmosis only indicated past infection. Similarly, quantitative polymerase chain reaction (PCR) in blood for herpes simplex virus (HSV), varicella-zoster virus (VZV), Epstein-Barr virus (EBV), adenovirus, human herpes virus 6, parvovirus B19, and hepatitis B and C virus were all negative. On the contrary, CMV PCR was strongly positive (7000 copy/mL). Thus, consistent with the result of CMV pp65 antigenemia, CMV was diagnosed as the main pathogen of fulminant myocarditis. Because administration of ganciclovir was started, her general condition dramatically improved, CMV antigenemia decreased to negative value after the transient increase (peak, 365 positive cells in 2 slides), and all of mechanical cardiopulmonary support devices were successfully removed at 2 weeks after their initiation (Figure 1). Five months after transplantation, she remains in complete remission, without evidence of heart failure or cardiogenic shock.

CMV infection is a major cause of morbidity and mortality after hematopoietic stem cell transplantation (HSCT). Although CMV is a common pathogen of myocarditis in heart transplant recipients [4], there were few reports on this disease after allogeneic HSCT. In this case, she developed presumed fulminant CMV myocarditis after allogeneic BMT, and was successfully treated with antiviral therapy and mechanical circulatory support. Fulminant myocarditis is characterized by an acute onset of severe hemodynamic instability, and has better long-term prognosis than patients with nonfulminant myocarditis if recognized promptly and successfully managed with appropriate supportive care with inotropes or mechanical circulatory support [3]. Thus, initiation of mechanical circulatory support should be useful as a bridge to recovery for the treatment of fulminant myocarditis even in allogeneic HSCT recipients. Considering the efficacy of antiviral therapy, CMV myocarditis should be taken into account when a patient develops a sudden onset of acute heart failure or cardiogenic shock after allogeneic BMT.

ACKNOWLEDGMENTS

Financial disclosure: The authors have nothing to disclose.

REFERENCES

1. Aretz HT, Billingham ME, Edwards WD, et al. Myocarditis. A histopathologic definition and classification. *Am J Cardiovasc Pathol.* 1987;1:3-14.
2. Gupta S, Markham DW, Drazner MH, Mammen PP. Fulminant myocarditis. *Nat Clin Pract Cardiovasc Med.* 2008;5:693-706.
3. McCarthy RE 3rd, Boehmer JP, Hruban RH, et al. Long-term outcome of fulminant myocarditis as compared with acute (non-fulminant) myocarditis. *N Engl J Med.* 2000;342:690-695.
4. Powell KF, Bellamy AR, Catton MG, et al. Cytomegalovirus myocarditis in a heart transplant recipient: sensitive monitoring of viral DNA by the polymerase chain reaction. *J Heart Transplant.* 1989;8:465-470.

Keisuke Kataoka
Tsuyoshi Takahashi
Hiroshi Iwata
Akira Hangaishi
Keiki Kumano
Mineo Kurokawa

¹Department of Hematology & Oncology
Graduate School of Medicine
University of Tokyo
Tokyo, Japan

²Department of Cardiovascular Medicine
Graduate School of Medicine
University of Tokyo
Tokyo, Japan

³Department of Cell Therapy and Transplantation Medicine
University of Tokyo Hospital
Tokyo, Japan

Biol Blood Marrow Transplant 16: 129-130 (2010)

© 2010 American Society for Blood and Marrow Transplantation

doi:10.1016/j.bbmt.2009.05.008

Chromosomally Integrated Human Herpesvirus 6: Transmission via Cord Blood-Derived Unrelated Hematopoietic Stem Cell Transplantation

In 1997, Daibata et al. [1] highlighted the remarkable chromosomal integration of human herpesvirus 6 (HHV6) DNA. We identified a unique case of chromosomally integrated HHV6 (CI-HHV6) after uncomplicated successful unrelated cord blood stem cell transplantation (CBT).

A 1.8-year-old boy with mucopolysaccharidosis type I (Hurler phenotype) was referred for CBT and received a myeloablative (MA) conditioning regimen (busulfan [Bu] 480 mg/m², cyclophosphamide [Cy] 200 mg/kg), including serotherapy with thymoglobulin (Genzyme Corporation, Cambridge, MA). Subsequently, a total of 1.5×10^5 CD34⁺ and 2.5×10^7 nucleated cells/kg of the recipient bodyweight were infused. As graft-versus-host disease (GVHD) prophylaxis, cyclosporine A (CsA; dose is based on plasma

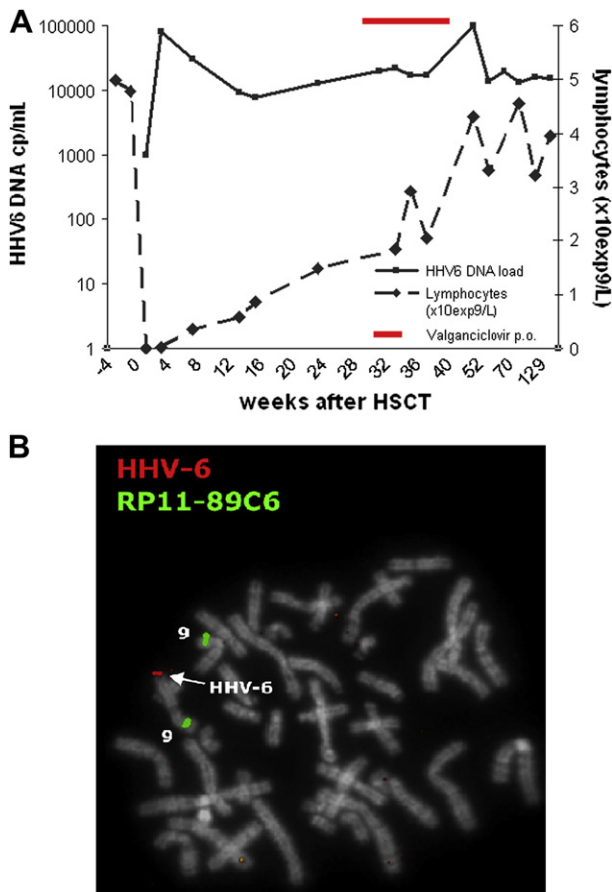


Figure 1. (A) HHV6 DNA load and lymphocyte engraftment after HSCT. (B) FISH signals on a representative metaphase cell with cohybridization of a control probe from 9p (in green) and an HHV6 specific probe (in red) showing integration of HHV6 at the telomere region of the long arm of chromosome 9 (arrow).

levels: 200-250 $\mu\text{g/L}$) and prednisolone (1 mg/kg until day +28 after CBT, with a taper in 14 days) were administered. Neutrophil engraftment ($>0.5 \cdot 10^9$ cells/L) occurred on day +18, platelet engraftment was noted on day +28 ($>50 \cdot 10^9$ cells/L), and stable 100% chimerism was achieved.

The recipient was seropositive for HHV6 prior to CBT. HHV6 DNA load, measured by quantitative real-time polymerase chain reaction (PCR), in plasma on days -32, -14, and -7 were negative, but appeared positive only a few hours after CB stem cell infusion (day 0) [2]. HHV6 DNA load increased and remained highly positive (10^5 cp/mL) for more than 2.5 years. Antiviral treatment with valganciclovir (20 mg/kg/day) was ineffective (Figure 1A). Therefore, we hypothesized CI-HHV6 transmitted via CBT. In retrospect, CB unit-derived DNA appeared to be highly HHV6 DNA positive (10^7 cp/mL). We analyzed HHV6 positivity in various cell populations (pure CD4^+ T cells, CD8^+ T cells, CD19^+ B cells, monocytes and natural killer [NK] cells), sorted by fluorescein-activated cell sorting, in a stored sample from 6 months after CBT. Remarkably, all populations were

highly positive for HHV6 DNA, whereas latent HHV6 infection is characterized by HHV6 positivity in the T cell population only [3]. Hair follicles were negative for HHV6 DNA, indicating that the recipient is CI-HHV6 negative. Finally, fluorescein in situ hybridization (FISH) analysis of chromosome preparations made from phytohemagglutinin-stimulated peripheral blood cultures was performed as described [4] and revealed CI-HHV6 on the telomeric site of the long arm of chromosome 9 (Figure 1B). As this patient had achieved 100% donor chimerism, this CI-HHV6 originated from the CB unit. Others have shown an incidence of asymptomatic CI-HHV6 in healthy newborns of 0.86%; thus, there is a possible incidence of 0.86% CI-HHV6 in CBTs [5].

The pattern of HHV6 DNA load in plasma can easily be misinterpreted as HHV6 reactivation or infection, as previously observed [6-9]. Our case highlights the importance of PCR analysis of the CB unit to distinguish patients with HHV6 reactivation from patients with CI-HHV6 to prevent administration of unnecessary toxic antiviral treatment.

ACKNOWLEDGMENTS

Financial disclosure: The authors thank the Department of Genetics, UMC Utrecht, The Netherlands, for their help in preparing chromosomal suspensions, the Department of Metabolic Disorders, Academic Medical Center, The Netherlands for kindly providing a serum sample, and K. Gaiser, technician at the Department of Immunology, for cell sorting. All authors declare no conflict of interest. A.V. was supported by a grant from the Anthony Nolan Trust.

REFERENCES

- Daibata M, Taguchi T, Sawada T, Taguchi H, Miyoshi I. Chromosomal transmission of human herpesvirus 6 DNA in acute lymphoblastic leukaemia. *Lancet*. 1998;15(352):543-544.
- de Pagter PJ, Schuurman R, Visscher H, et al. Human herpes virus 6 plasma DNA positivity after hematopoietic stem cell transplantation in children: an important risk factor for clinical outcome. *Biol Blood Marrow Transplant*. 2008;14:831-839.
- Takahashi K, Sonoda S, Higashi K, et al. Predominant CD4 T-lymphocyte tropism of human herpesvirus 6-related virus. *J Virol*. 1989;63:3161-3163.
- Nacheva EP, Ward KN, Brazma D, et al. Human herpesvirus 6 integrates within telomeric regions as evidenced by five different chromosomal sites. *J Med Virol*. 2008;80:1952-1958.
- Hall CB, Caserta MT, Schnabel K, et al. Chromosomal integration of human herpesvirus 6 is the major mode of congenital human herpesvirus 6 infection. *Pediatrics*. 2008;122:513-520.
- Clark DA, Nacheva EP, Leong HN, et al. Transmission of integrated human herpesvirus 6 through stem cell transplantation: implications for laboratory diagnosis. *J Infect Dis*. 2006;1(193):912-916.
- Kamble RT, Clark DA, Leong HN, Heslop HE, Brenner MK, Carrum G. Transmission of integrated human herpesvirus-6 in allogeneic hematopoietic stem cell transplantation. *Bone Marrow Transplant*. 2007;40:563-566.
- Troy SB, Blackburn BG, Yeom K, Caulfield AK, Bhangoo MS, Montoya JG. Severe encephalomyelitis in an immunocompetent

adult with chromosomally integrated human herpesvirus 6 and clinical response to treatment with foscarnet plus ganciclovir. *Clin Infect Dis*. 2008;47:e93-e96.

9. Jeulin H, Salmon A, Gautheret-Dejean A, et al. Contribution of human herpesvirus 6 (HHV-6) viral load in whole blood and serum to investigate integrated HHV-6 transmission after haematopoietic stem cell transplantation. *J Clin Virol*. 2009.

P. J. de Pagter

Anne Virgili

Ellie Nacheva

Debbie van Baarle

Rob Schuurman

Jaap J. Boelens

¹Department of Immunology/Haematology and HSCT

University Medical Center Utrecht, Utrecht

The Netherlands

²Department of Haematology

University College London Medical School

Royal Free Campus

London, United Kingdom

³Department of Virology

University Medical Center Utrecht

Utrecht, The Netherlands

Biol Blood Marrow Transplant 16: 130-132 (2010)

© 2010 American Society for Blood and Marrow Transplantation

doi:10.1016/j.bbmt.2009.05.009

CCR5 Expression on Cells from HLA-Matched Unrelated Marrow Donors and Graft-versus-Host Disease

Graft-versus-host disease (GVHD) is a common complication that is caused by donor T cells following allogeneic hematopoietic cell transplant. Recently, the functional state of T cells has been characterized by their chemokine receptor expression pattern [1]. T cells expressing chemokine receptor CCR5 contribute

to the rejection of solid organ allografts [2] and development of murine GVHD [3-5]. A nonfunctional mutant allele of CCR5, CCR5 Δ 32, is found with 10% frequency in Caucasians [6,7]. In a study of renal-transplant survival, patients homozygous for CCR5 Δ 32 had significantly prolonged graft survival compared to heterozygous or wild-type patients [8]. Here, we retrospectively compared outcomes among patients receiving marrow grafts from unrelated donors homozygous for CCR5 Δ 32 to those from donors expressing CCR5.

We screened the donor DNA repository at Fred Hutchinson Cancer Center for the CCR5 Δ 32 mutation by a PCR method [9]. Among 1273 donors, 9 were homozygous for CCR5 Δ 32. Recipients of those bone marrow (BM) grafts were predominantly cytomegalovirus (CMV) patients (CMV = 8; acute myelogenous leukemia [AML] = 1), and we therefore decided to confine our study to the CMV patient group. Patients were 18 to 50 years old and transplanted between 1988 and 2000. They received cyclophosphamide (Cy) and fractionated total body irradiation, unmanipulated marrow, and GVHD prophylaxis with cyclosporine (CsA) and methotrexate (MTX) [9]. A total of 344 CMV patients had a CCR5 wild-type donor, 39 had a CCR5 Δ 32 heterozygous donor, and 8 had a CCR5 Δ 32 homozygous donor. Logistic regression model was used to assess the association between CCR5 genotype and acute GVHD (aGVHD), and Cox regression was used for chronic GVHD (cGVHD) and relapse. As shown in Table 1, there was less GVHD among patients whose donor was CCR5 Δ 32 homozygous compared to patients with a wild-type or heterozygous donor, although most of the differences are not statistically significant. The number of patients with a homozygous donor is small, making it difficult to derive firm conclusions even where results are suggestive of a true difference. Moreover, there are several factors that have an impact on GVHD, relapse, and mortality. With only 8 patients with a homozygous donor, we made limited adjustments. After controlling for severity of disease (categorized as low [chronic phase] versus intermediate [accelerated phase or blast crisis in remission] versus

Table 1. Transplant outcomes of patients receiving unrelated marrow grafts from CCR5 wild-type (+/+), CCR5 Δ 32 heterozygous (+/-) or CCR5 Δ 32 homozygous (-/-) donors.

	+/+ (n = 344)	+/- (n = 39)	-/- (n = 8)
Grades II-IV	309 (90%) OR = 1	34 (87%) OR = 0.77 (0.28-2.10, P = .61)	6 (75%) OR = 0.34 (0.07-1.75, P = .20)
Grades III-IV	124 (36%) OR = 1	13 (33%) OR = 0.89 (0.44-1.79, P = .74)	1 (13%) OR = 0.25 (0.03-2.08, P = .20)
Skin*	288 (84%) OR = 1	18 (46%) OR = 0.89 (0.37-2.11, P = .79)	4 (50%) OR = 0.19 (0.05-0.80, P = .02)
Liver*	159 (46%) OR = 1	32 (82%) OR = 0.65 (0.33-1.30, P = .22)	2 (25%) OR = 0.39 (0.08-1.95, P = .25)
Gut*	219 (64%) OR = 1	14 (36%) OR = 0.82 (0.42-1.61, P = .57)	5 (63%) OR = 0.95 (0.22-4.05, P = .95)
Chronic†	207 (60%) HR = 1	19 (49%) HR = 0.96 (0.60-1.53, P = .85)	3 (38%) HR = 0.45 (0.14-1.41, P = .17)
Relapse	66 (19%) HR = 1	9 (23%) HR = 1.71 (0.85-3.43, P = .13)	3 (38%) HR = 1.80 (0.57-5.71, P = .32)
Mortality	167 (49%) HR = 1	24 (62%) HR = 1.59 (1.04-2.44, P = .03)	4 (50%) HR = 1.01 (0.37-2.71, P = .99)

OR indicates odds ratio; HR, hazard ratio.

*Organ-specific graft-versus-host disease (GVHD) of any grade (I-IV).

†Clinical extensive chronic GVHD.