

Conflict of interest statement

The authors declare no COI exist.

L. Trodella
Department of Radiotherapy, University Campus
Biomedico, Rome, Italy

A. Cesario^{a,b,*}

^a Department of Thoracic Surgery, Catholic
University, Rome, Italy

^b Deputy Scientific Director, IRCCS San Raffaele
Pisana, Rome, Italy

* Corresponding author at: Scientific Direction,
IRCCS San Raffaele Pisana, Rome, Italy.
E-mail address: alfredo.cesario@sanraffaele.it
(A. Cesario)

16 January 2012

doi:10.1016/j.lungcan.2012.01.015

References

- [1] Brunelli A, Charloux A, Bolliger CT, Rocco G, Sculier JP, Varela G, et al. On behalf of the European Society of Thoracic Surgeons joint task force on fitness for radical therapy. *Eur J Cardiothorac Surg* 2009;36:181–4.
- [2] Arbane G, Tropman D, Jackson D, Garrod R. Evaluation of an early intervention after thoracotomy for non-small cell lung cancer (NSCLC), effects on quality of life, muscle strength and exercise tolerance: randomised controlled trial. *Lung Cancer* 2011;71:229–34.
- [3] Granger CL, McDonald CF, Berney S, Chao C, Denehy L. Exercise intervention to improve exercise capacity and health related quality of life for patients with non-small cell lung cancer: a systematic review. *Lung Cancer* 2011;72:139–53.
- [4] Cesario A, Ferri L, Galetta D, Pasqua F, Bonassi S, Clini E, et al. Post-operative respiratory rehabilitation after lung resection for non small cell lung cancer. *Lung Cancer* 2007;57:175–80.
- [5] Cesario A, Ferri L, Galetta D, Cardaci V, Piratino A, Bonassi S, et al. Pre-operative pulmonary rehabilitation and surgery for lung cancer. *Lung Cancer* 2007;57(July (1)):118–9.
- [6] Cesario A, Dall'Armi V, Cusumano G, Ferri L, Margaritora S, Cardaci V, et al. Post-operative pulmonary rehabilitation after lung resection for NSCLC: a follow up study. *Lung Cancer* 2009;66(November (2)):268–9.

F. Pasqua

Department of Pulmonary Rehabilitation, IRCCS San
Raffaele Pisana – SR Velletri Unit, Rome, Italy

R. D'Angelillo

Department of Radiotherapy, University Campus
Biomedico, Rome, Italy

F. Mattei

S. Bonassi

Unit of Clinical and Molecular Epidemiology, IRCCS
San Raffaele Pisana, Rome, Italy

G.L. Biscione

K. Geraneo

Department of Pulmonary Rehabilitation, IRCCS San
Raffaele Pisana – SR Velletri Unit, Rome, Italy

V. Cardaci

Department of Pulmonary Rehabilitation, IRCCS San
Raffaele Pisana, SR Pisana Unit, Rome, Italy

L. Ferri

Department of Pulmonary Rehabilitation, IRCCS San
Raffaele Pisana – SR Cassino Unit, Italy

S. Ramella

Department of Radiotherapy, University Campus
Biomedico, Rome, Italy

P. Granone

Department of Thoracic Surgery, Catholic University,
Rome, Italy

S. Sterzi

Department of Physical and Rehabilitative Medicine,
Campus Biomedico University, Rome, Italy

E. Crisafulli

E. Clini

Pulmonary Rehabilitation, Villa Pineta Hospital,
Pavullo (Modena), Italy

F. Lococo

Department of Thoracic Surgery, Catholic University,
Rome, Italy

Non-small cell lung carcinoma of donor origin after bilateral lung transplantation**Keywords:**

Lung transplantation
Immunosuppression
Lung cancer
Donor origin
Non-small cell lung cancer
Cystic fibrosis

To the Editor,

Von Boehmer et al. described a patient who received bilateral lung transplantation and presented with a non-small cell lung carcinoma (NSCLC) of donor origin 7 months later [1]. Thus far only 3 cases of lung cancer of donor origin after bilateral lung transplantation have been described in the literature, two cases of NSCLC [1,2] and 1 case of small cell lung carcinoma [3]. Here we present one more patient with non-small cell lung carcinoma of donor origin.

A male patient with a history of cystic fibrosis with chronic *Pseudomonas* colonization received bilateral lung transplantation at the age 17. The patient recovered well. The donor was a 56-year-old woman who died of a cerebral bleeding with no relevant medical history and no smoking history. Both donor and acceptor were Cytomegalovirus and Epstein-Barr virus negative. Immunosuppressive therapy consisted of Basiliximab for induction, Tacrolimus, Mycophenolate and Prednisolon. In the years after the transplantation the patient had a few episodes of pneumonia due to *Pseudomonas aeruginosa* infection and a primary infection of Epstein-Barr virus. Five years after his transplantation he had a decreased lung function associated with an infection with rhinovirus and was successfully treated with Methyl-prednisolon. Six months later the patient again had a decrease in lung function. Computed Tomography scan revealed enlarged mediastinal lymph nodes which appeared to be positive with Positron Emission Tomography. During bronchoscopy no abnormalities were found and cytology of the bronchoalveolar lavage fluid only showed inflammation. In the cultures of the bronchoalveolar lavage fluid an infection with *P. aeruginosa* was demonstrated. A mediastinoscopy was performed.

The mediastinal lymph nodes biopsies showed metastasis of a poorly differentiated carcinoma to the lymph nodes (Naruke 7, Naruke 4R and 4L and Naruke 2R; Fig. 1A). Immunohistochemical analysis of the metastasis revealed an immunohistochemical profile (Cytokeratin 7 and thyroid transcription factor-1 positive, thyroglobulin negative) compatible with lung adenocarcinoma (Fig. 1B). With High Resolution Melt (HRM) analysis and sequence

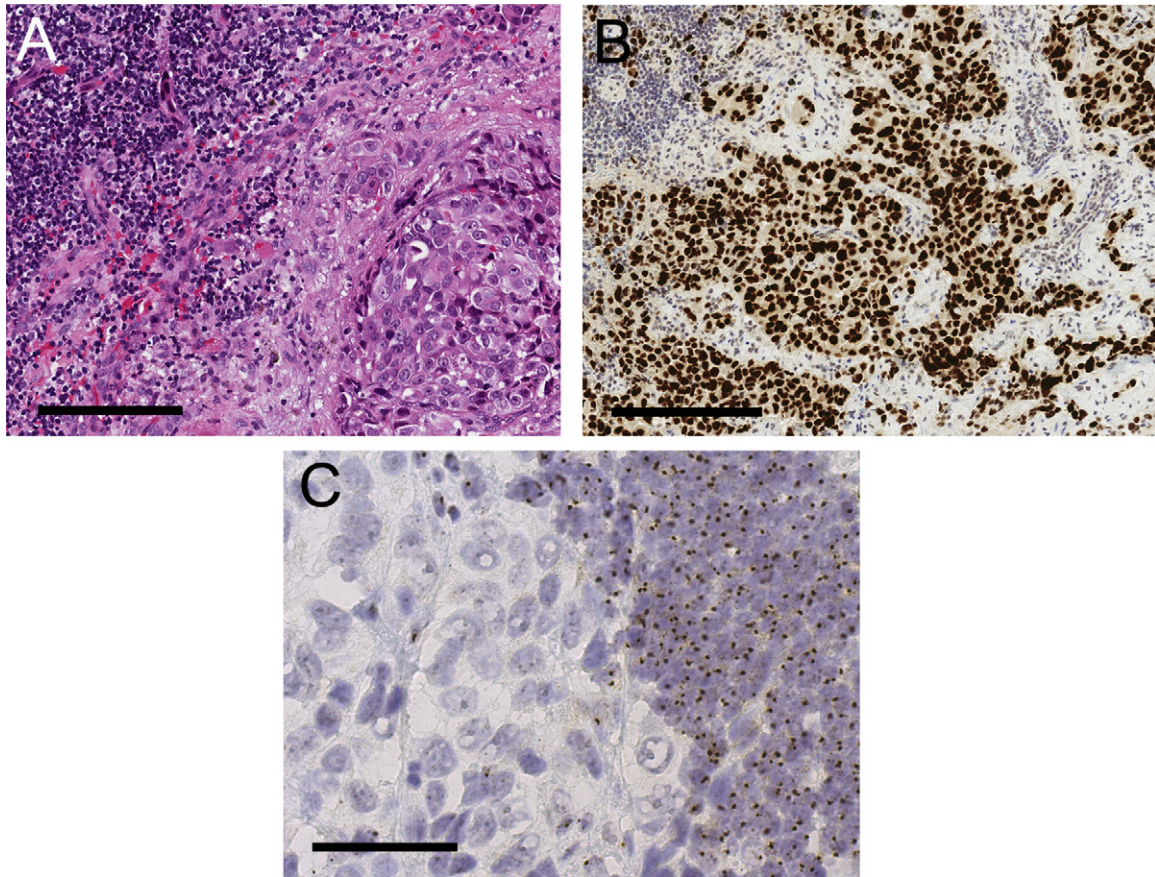


Fig. 1. Microscopic analysis of mediastinal lymph nodes. (A) Haematoxylin and eosin staining showing lymphoid tissue at the left side and tumour cells with enlarged irregular nuclei at the right side. Bar = 100 μm . (B) Immunohistochemical staining with an antibody directed against thyroid transcription factor-1 (TTF-1). The nuclei of the tumour cells show nuclear staining, compatible with lung adenocarcinoma. Bar = 200 μm . (C) In situ hybridisation of the Y-chromosome showing one brown dot in the nuclei of the lymphocytes (right side), which demonstrates the recipient origin of the lymphocytes. In the nuclei of the tumour cells (left side), no dots are visible, which demonstrates absence of the Y chromosome. Bar = 50 μm . (For interpretation of the references to colour in this figure legend, the reader is referred to the web version of this article.)

analysis of exons 2 and 3 of the KRAS genome, a point mutation in codon 61 was demonstrated. No mutations of EGFR (exons 19, 20 and 21) were identified with HRM. In situ hybridisation of the X chromosome and Y chromosome showed that the tumour cells contained at least 2 X-chromosomes and no Y-chromosome, while the preexisting lymphocytes contained 1 Y-chromosome and 1 X-chromosome (Fig. 1C). Tissue identification (by polymerase chain reaction and sequencing) demonstrated 11/15 different Short Tandem Repeats (STRs) and amelogenin in the lymph node biopsies with tumour compared with the DNA of the patient. This confirmed the donor origin of the carcinoma.

Re-analysis of the high resolution Computed Tomography scan revealed no significant lesion in the lungs, although there was a PET positive infiltration/atelectasis in the right under lobe which earlier was thought to be caused by an infection with *P. aeruginosa*. One month after the initial diagnosis the patient developed carcinomatous pleuritis of the right pleural space which was treated with pleurodesis. Because of the stage IV disease, it was decided not to treat the patient with chemotherapy due to expected complications in combination with the immune suppressive therapy.

As indicated by Von Boehmer et al., immunosuppression in association with organ transplantation is required to protect the graft from rejection, but concomitantly compromises immunological control mechanisms against infectious diseases and cancer. In the present case a patient developed an adenocarcinoma in a transplanted lung that was received from a donor with limited risk

factors for lung cancer development. This might suggest that the suppression of the immune system has led to accelerated development of a carcinoma in the lung that has metastasized already when the primary lesion could not be detected with imaging techniques. Since this is only the fourth case described of lung cancer developed in the donor lung, further survey of donor developed lung carcinoma in the transplanted population is needed to get further experience with diagnosis and treatment of this patient group.

Disclosures

None.

Conflict of interest statement

None declared.

References

- [1] Von Boehmer L, Draenert A, Jungraithmayr W, Inci I, Niklaus S, Boehler A, et al. Immunosuppression and lung cancer of donor origin after bilateral lung transplantation. Lung Cancer November 2011 [Epub ahead of print].
- [2] Beyer EA, DeCamp MM, Smedira NG, Farver C, Mehta A, Warshawsky I. Primary adenocarcinoma in a donor lung: evaluation and surgical management. J Heart Lung Transplant 2003;22:1174–7.
- [3] De Soyza AG, Dark JH, Parums DV, Curtis A, Corris PA. Donor-acquired small cell lung cancer following pulmonary transplantation. Chest 2001;120:1030–1.

Mirthe de Boer*
Aryan Vink
*Department of Pathology, University Medical Center
Utrecht, Utrecht, The Netherlands*

Ed A. van de Graaf
*Department of Respiratory Medicine, University
Medical Center Utrecht, Utrecht, The Netherlands*

* Corresponding author at: University Medical
Center Utrecht, Department of Pathology, Room H
04.312, Heidelberglaan 100, 3584 CX Utrecht,
The Netherlands.
E-mail address: mirthe.deboer@gmail.com
(M. de Boer)

6 February 2012

doi:10.1016/j.lungcan.2012.02.010